

A 30-Month Follow-Up of Stepwise Excavation without Re-entry with Three Different Biomaterials: A Case Report

S. Banava¹, M. Safaie Yazdi², M. Safaie Yazdi³.

¹Assistant Professor, Department of Restorative Dentistry, School of Dentistry, Islamic Azad University, Dental Branch, Tehran, Iran

²Dentist

³Endodontist

Abstract

Background and Aim: Restoration of deep dental caries without pulp exposure is usually challenging for dentists. In order to prevent pulp exposure and subsequent root canal therapy (RCT), indirect pulp capping is usually performed. Stepwise excavation (SE) is a conservative method that can reduce the incidence of pulp exposure and maintain tooth vitality without the need for RCT. Considering the high prevalence of dental caries among the Iranian population, knowledge about this treatment modality can be beneficial for dentists.

Case Report: A 23 year-old patient with three deep carious lesions presented to our dental clinic. The teeth had normal responses to thermal tests and percussion. Due to the high risk of pulp exposure following conventional complete excavation of caries, stepwise excavation treatment was done. Three different lining materials (calcium hydroxide, MTA, CEM cement) were used to cover the remaining caries. The teeth were restored using posterior restorative glass ionomer (Fuji9, GC, USA). The teeth were followed weekly in the first month and then every six months up to 30 months clinically and radiographically. At 30-month follow-up, the teeth did not show any sensitivity to cold or percussion, had no spontaneous nocturnal pain or irreversible pulpitis symptoms and did not need RCT; these signs were all indicative of a successful treatment.

Key Words: Stepwise excavation, Liner, MTA, Calcium hydroxide, CEM cement, pulp exposure, Caries removal

✉ Corresponding author:
S. Banava, Assistant Professor,
Department of Restorative
Dentistry, School of Dentistry,
Islamic Azad University, Dental
Branch, Tehran, Iran
sbanava@yahoo.com

Received: 28 Jan 2013
Accepted: 18 April 2013

Journal of Islamic Dental Association of IRAN (JIDAI) Autumn 2013 ;25, (4)

Introduction

Deep carious lesions cause severe inflammatory reactions in dental pulp and can proceed to pulp necrosis [1-4]. Conventional restorative treatments suggest complete removal of carious dentin, while this procedure may lead to pulp exposure [1-7]. It has been shown that complete excavation of caries in a single visit can increase the chance of pulp exposure by up to 53% [4]. In this situation, considering the clinical symptoms, pulp capping, pulpotomy or pulpectomy are performed [1-2, 8-10]. The more conservative the cavity preparation and

caries excavation, the lower the chance of pulp exposure [4-6, 8-12].

Preservation of pulp vitality is among the main priorities in dentistry [1-3]. Conservative dental treatments with reasonable costs are more acceptable by patients. This issue is especially important in countries where the insurance companies do not cover dental treatments. As the result, people with deep carious lesions who cannot afford a restoration treatment prefer to extract their teeth instead of restoring it in order not to bear the heavy costs of root canal therapy and subsequent restorative pro

cedures [13].

There are different treatment options for teeth with deep carious lesions and risk of pulp exposure but with normal symptoms. In 1938, Bodecker introduced the Stepwise Excavation technique for preservation of pulp vitality and conservative treatment of teeth with deep caries [5]. SE has gained a growing interest in the recent years from different researchers due to advances made in techniques and dental materials with good sealing ability and antibacterial properties. Unlike Indirect pulp capping, in the first step of SE, caries are completely removed from the periphery of the cavity, but a layer of carious dentin is left behind on pulpal or axial wall, where exposure of pulp is probable. Compared to complete excavation in a single visit, using this technique will decrease the risk of pulp exposure by up to 15% via decreasing the microbial count in the remained caries and providing an opportunity for the pulp to defend itself [3,5,9]. After a variable period of 1 to 12 months [14], the cavity is re-opened and the remained caries that are now darker in color and harder in consistency than before are removed. Different studies have proven that in the second step, the cultivable flora is different and non-cariogenic. Some randomized clinical trials support the superior success rate of this technique over the single-visit complete excavation technique [7-10].

Recently, it has been suggested to avoid the second step of SE and not to open the cavity for the second time. There is only one study regarding this technique with a 12-month follow up [16] and no long-term studies in this respect.

Different studies have suggested that placing a lining material with antibacterial effects and sealing ability over the remaining caries can have a positive role in the success of SE [3,12].

Several materials have been used as liner in SE technique, such as calcium hydroxide, zinc oxide eugenol, glass ionomer, adhesive and composite resins and also different restorative materials such as amalgam, composite resins and glass ionomers [3]. Calcium hydroxide (CH) is the most commonly used material to cover the remaining caries [4-12,14-16]. CH is a high pH, biocompatible material with antibacterial properties. It also plays a positive role in the production of dentinal bridge. The downside of CH is its solubility in long-term that

leads to microleakage [17, 18]. Due to this drawback, clinicians are looking for a more appropriate lining material for SE.

MTA (Mineral Trioxide Aggregate) was recently introduced as a biocompatible material with a high pH, antibacterial effect and several other optimal properties. This material is a mixture of tricalcium silicate, tricalcium aluminate, tricalcium oxide and silicate oxide [2,19]. MTA has never been used for SE but considering its optimal properties, it may be a good candidate for this purpose.

Another biomaterial called CEM cement (Calcium Enriched Material) was recently produced in Iran. CEM cement contains different calcium compounds such as calcium oxide, calcium hydroxide, calcium carbonate, calcium silicate, calcium phosphate and some other ingredients [20]. Properties of CEM cement are similar to those of MTA, such as its antibacterial effect, sealing ability and induction of dentinal bridge formation. CEM cement has not been used for SE either.

Case selection plays a critical role in SE technique. To achieve a successful outcome, clinical and radiographic symptoms have to be considered carefully [23]. A one year follow up of SE cases shows 74%-91% survival in comparison with direct complete excavation [24]. Any sign of irreversible pulpitis or the need for root canal therapy is considered as a failure for SE technique [13, 14].

The objective of this study was to describe the treatment of three teeth with deep carious lesions and high risk of pulp exposure using three different lining materials and their 30-month follow up.

Case Report

A 23 year-old female patient was referred to the Department of Restorative Dentistry at Islamic Azad University of Tehran for dental treatment. After the evaluation of teeth using the ICDAS (International Caries Detection and Assessment System) [25], three teeth (# 14, 15 & 18) were found to have code 4 caries in ICDAS, which is indicative of deep caries. Radiographic assessment showed deep caries extending by up to $\frac{3}{4}$ of the distance between the DEJ and pulp chamber carrying a high risk of pulp exposure in case of complete caries removal in the involved teeth especially the lower left second molar which also had a slight PDL widening. The remaining teeth did not

have any periapical lesion or PDL widening. (Figure 1)

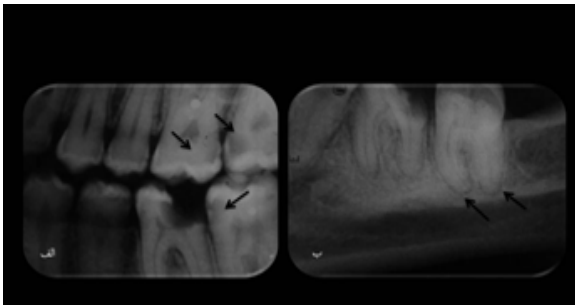


Figure 1. a: Radiograph revealing deep caries in teeth no. 14,15& 18 (arrows),
b: Radiograph of tooth no.18 showing a slight PDL widening (arrow).

A clinical examination was carried out to ensure the normal reaction of the teeth. There was no sensitivity to cold after a 5-second contact with Green Endo Ice refrigerant spray (ColteneWhaledent, NJ, USA) and the teeth with deep caries were similar to the corresponding teeth in the opposite quadrant in terms of VAS (Visual Analog Scale). In total, based on clinical and radiographic examinations, the teeth had normal vital signs. But, because of their deep carious lesions and high risk of pulp exposure in case of complete excavation of caries, SE technique was selected as the treatment of choice. The treatment process was described to the patient and an informed consent was obtained.

The teeth were isolated and prepared without anesthesia to evaluate the pulp response to caries removal [26]. Cavity preparation was done by a diamond fissure #008 (D&Z Co., Germany) under copious water spray.

After preparing the outline form in each tooth and entering the cavity, the caries were removed from all carious walls except for the axial and pulpal walls to avoid pulp exposure. The axial wall caries were removed according to Bjorndal [15, 23] by excavating the soft and wet part of the lesion using a round low-speed carbide bur but the deeper part was remained undisturbed. The patient did not experience any pain during the process of caries removal.

In the next step, a sectional matrix was placed adjacent to the proximal cavity and secured with an anatomical wooden wedge. The lining material

was randomly selected by rolling a dice for each tooth. Application of each biomaterial was done according to its manufacturing instructions as follows:

Left upper first molar with disto-occlusal cavity, assigned for CH (Dycal, Dentsply, USA) application: According to the manufacturer's instructions, equal volumes of base and catalyst pastes were mixed thoroughly for 10 seconds until a uniform color was achieved. It was applied to the carious lesion in axial wall using a small ball burnisher. Cavity was conditioned with GC Dentine Conditioner (GC, USA) for 20 seconds, rinsed with water and dried with a cotton pellet without desiccating and filled with EQUIA system (GC, USA) restorative material. The posterior glass ionomer capsule in this system was mixed in an amalgamator for 10 seconds as instructed by the manufacturer. The cavity was filled with GI and left undisturbed. After 15 minutes, the restorative material was finished and polished and a resin-based sealing material available in the EQUIA kit (G-coat, GC, USA) was applied to the restoration surface in a single layer and light cured for 40 seconds with a Quartz-Tungsten_Halogen light curing unit with the light intensity of 800 mW/cm² to seal the restoration as recommended by the manufacturer.

Left upper second molar with a mesio-occlusal cavity assigned for capping with MTA: After isolating the tooth, the powder and liquid of the MTA (ProRoot, Dentsply, USA) were mixed until a suitable consistency was achieved. The material was placed over the axial wall and remained undisturbed with a wet cotton pellet on it, for 15 minutes [27]. After initial setting of MTA, the cavity was restored with EQUIA system as mentioned earlier.

The lower left second molar assigned to be lined by CEM cement (Yektazist, Iran): The cement was mixed according to the manufacturer's instructions and applied to the axial wall and left undisturbed for 15 minutes with a wet cotton pellet over it. The cavity was restored and finished as described. (Figure 2) Immediately after treatment, a parallel periapical radiograph was taken. The patient was followed up by phone on days 3 and 7 and then weekly for 8 weeks. On follow ups, she was asked about her symptoms such as pain, sensitivity to cold or heat and sweet or sour food. At 8 weeks and after that every 6 months the patient was clinically and radi-

ographically examined and sensitivity to cold, pressure and percussion was assessed.

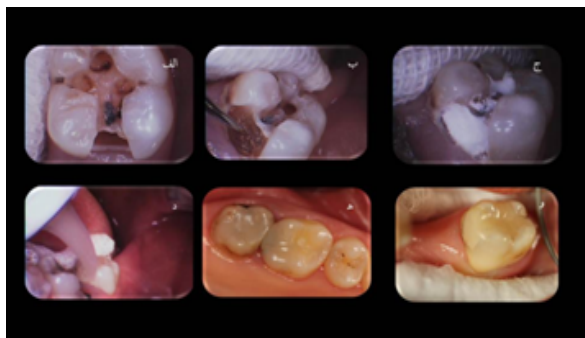


Figure 2. Clinical procedure of SE without re-entry: a&b: Initial cavity revealing deep caries, c: Caries removal from the walls, d: Liner application, e: Restorative material application (Fuji IX Glass Ionomer), f: Clinical view after 30 months

During the 30-month follow up, the patient reported no sensitivity or discomfort. Pulp vitality was confirmed at each follow up session with a positive but within the normal range response to cold test, no spontaneous pain and no periapical lesion or PDL widening [15,16]. The widened PDL in the lower left second molar had no progression. (Figure 3)

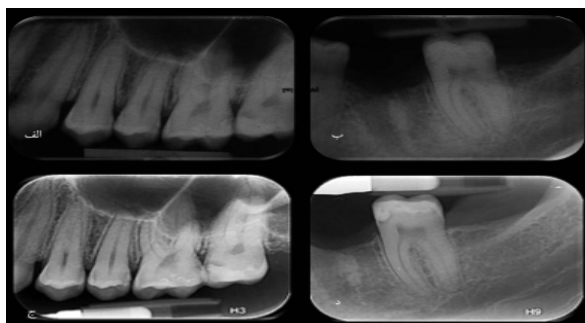


Figure 3. a & b: Radiographs at 12-month follow up, c: Radiographs at 30-month follow up

Discussion

The current report shows successful outcome of 3 teeth treated with stepwise excavation technique at 30-month follow up. However, longer follow-ups are still required to cast a final judgment. Application of suitable materials and cavity sealing reduce the number of residual bacteria and increase the success rate of restorative treatments in long-term

[5,15]. In this report, three different liners were applied to cover the remained caries. CH, a commonly used liner in dental treatments has been suggested and studied for use in SE but several studies have shown its reduced treatment success rate due to its long-term solubility [17,18].

During the 30-month follow up of our patient in this report, the tooth with CH liner application did not show any pain, irreversible pulpitis symptoms or periapical radiolucency but during the first few weeks the patient reported sensitivity to cold within the normal range.

MTA cement used in another tooth of our patient caused no clinical or radiographic symptoms, no signs of irreversible pulpitis, spontaneous pain, night pain, sensitivity to cold or percussion. The tooth treated with MTA did not need RCT either. This finding may be attributed to the high antibacterial property of MTA [18]. The only surprising finding about this material was black discoloration in the walls of the restored tooth after a few weeks even though we used white MTA. This finding was in accordance to recent researches on this cement [24] and can compromise and minimize the application of this material in the anterior teeth. Since MTA has not been used for SE in any other study, comparison of the results is not possible but our obtained findings were promising.

Similar to MTA, application of CEM cement used for the first time for SE in Iran did not cause any clinical symptoms indicative of failure or need for RCT. It was surprising that the radiolucency of the tooth with PDL widening and no pain on percussion resolved during the 30-month follow-up and the tooth remained vital. It seems that the antibacterial property and biocompatibility of this material like MTA were effective in reducing the bacterial mass in the remained caries. Future studies especially randomized clinical trials (RCT) are required on these two biomaterials for application in single step SE treatment of deep caries to assess their long-term success.

Single-step SE has been suggested by some researchers [15-16]. The one step method has lower risk of future complications but both the liner and the restorative material should provide very good seal [15,23]. In the current case report, the teeth were restored in one session with a recently introduced glass ionomer for posterior teeth restoration

as a substitute for amalgam or composite resin. The chemical bond between the glass ionomer and the tooth structure, fluoride release five times higher than other glass ionomer cements, high compressive strength (260 Mpa), low solubility and wear [28-29] and antibacterial property [26] were the reasons for selection of this restorative material for our patient. In this material, polyacrylic acid is used to condition and prepare the enamel and dentine surface for bonding. Since this material is self-cure, it sets in a short time and can be immediately finished and polished. A hydrophobic nanofilled resin is applied to the finished cement that adheres to the cement surface and because of its hydrophobicity, protects the material from further solubility and water sorption in the oral cavity [28-29]. Because of the mentioned advantages, we used this material as our final restorative material to avoid the disadvantages of amalgam and composite resin; which are commonly used for SE. Leakage, long distance and low intensity of light curing device, polymerization shrinkage and monomer-polymer conversion rate are among the drawbacks and problem associated with the mentioned materials that can compromise restoration sealing and account for leakage and solubility of liner materials.

Previous studies have usually reported SE technique done in two sessions [15,4]. Maltz et al, study can somehow be considered as single-step since some patients did not show up at the 12-month follow up but our study was the first to perform SE in a single session and follow up the patient for 30 months. However, future RCTs are still required to further elucidate this topic.

Conclusion

Based on the obtained results, the SE method can be used as a substitute for complete caries removal in cases with deep caries and no sign or symptoms of irreversible pulpitis and especially for low-income patients with high risk of dental caries. However, long-term clinical and radiographic follow-up of single visit SE treatments is required.

References

- 1- Roberson TM, Heyman H, Swift EM, Sturdevant CM. Sturdevant's art & science of operative dentistry. 5th ed. USA: Mosby; 2006, 67-114.
- 2- Schwartz R, Summitt J, Robbins JW, Santos J. Fundamentals of operative dentistry, 3rd ed. USA: Quintessence; 2001,81-86.
- 3- Kidd EA. How 'Clean' must a cavity be before restoration? Caries Res. 2004 May-Jun;38(3):305-13.
- 4- Ricketts DN, Kidd EA, Innes N, Clarkson J. Complete or ultraconservative removal of decayed tissue in unfilled teeth. Cochrane Database Syst Rev. 2006 Jul 19;(3):CD003808.
- 5- Bjørndal L, Larsen T. Changes in cultivable flora in deep carious lesions following a stepwise excavation procedure. Caries Res. 2000 Nov-Dec; 34(6):502-8.
- 6- Leksell E, Ridell K, Cvek M, Mejare I. Pulp exposure after stepwise versus direct complete excavation of deep carious lesions in young posterior permanent teeth. Endod Dent Traumatol. 1996 Aug;12(4):192-19.
- 7- Maltz M, Olivera EF, Fontanella V, Carminatti G. Deep caries lesions after incomplete dentine caries removal: 40-Month follow-up study. Caries Res. 2007; 41(6):493-6.
- 8- Olivera EF, Carminatti G, Fontanella V, Maltz M. The monitoring of deep caries lesions after incomplete dentine caries removal: results after 14-18 month. Clin Oral Investig. 2006 Jun;10(2):134-9.
- 9- Bjørndal L, Larsen T, Thylstrup A. A clinical and microbiological study of deep carious lesions during stepwise excavation using long treatment intervals. Caries Res. 1997;31(6):411-7.
- 10- Maltz M, Oliveira EF, Fontanella V, Bianchi R. A clinical, microbiologic, and radiographic study of deep caries lesions after incomplete caries removal. Quintessence Int. 2002 Feb;33(2):151-9.
- 11- Ricketts DN, Pitts NB. Novel operative treatment options. Monogr Oral Sci. 2009;21:174-87.
- 12- Ricketts D. Management of the deep carious lesion and the vital pulp dentine complex. Br Dent J. 2001 Dec 8; 191(11):606-10.
- 13- Banava S. [Stepwise Excavation: A conservative community-based dental. Treatment of deep caries to inhibit pulpal exposure.] Iranian J Publ Health. 2011 Fall; 40(3):140. (Persian)
- 14- Hayashi M, Fujitani M, Yamaki C, Momoi Y. Ways of enhancing pulp preservation by stepwise excavation-A systematic review. J Dent. 2011 Feb; 39(2):95-107.

- 15-Bjørndal L, Reit C, Bruun G, Markvart M, Kjældgaard M, Näsman P, et al. Treatment of deep caries lesions in adults: randomized clinical trials comparing stepwise vs. direct complete excavation, and direct pulp capping vs. partial pulpotomy. *Eur J Oral Sci.* 2010 Jun;118(3):290-7.
- 16-Maltz M, Garcia R, Jardim JJ, de Paula LM, Yamaguti PM, Moura MS, et al. Randomized trial of partial vs. stepwise caries removal: 3-year Follow-up. *J Dent Res.* 2012 Nov;91(11):1026-31.
- 17-Heitmann T, Unterbrink G. Direct pulp capping with a dentinal adhesive resin system: A pilot study. *Quintessence Int.* 1995 Nov;26(11):765-70.
- 18-Witherspoon DE, Small JC, Harris GZ. Mineral trioxide aggregate pulpotomies: A case series Outcome assessment. *J Am Dent Assoc.* 2006 May;137(5):610-8.
- 19- Parirokh M, Torabinejad M. Mineral Trioxide Aggregate: A Comprehensive literature review-part I: Chemical, physical, and antibacterial properties. *J Endod.* 2010 Jan;36(1):16-27.
- 20- Asgari S, Shahabi S, Jafarzadeh T, Amini S, Kheirieh S. [The properties of a new endodontic material.] *J Endod.* 2008 Aug; 34(8):990-3. (Persian)
- 21- Asgari S, Eghbal MJ, Parirokh M, Ghoddsi J, Kheirieh S, Brink F. [Comparison of mineral trioxide aggregate's composition with portland cements and a new endodontic cement.] *J Endod.* 2009 Feb;35(2): 243-50. (Persian)
- 22- Banava S, Heshmat H. [Dental Cements: Where, how, when? 1st ed.] Iran: Mir; 2011, 131-8. (Persian)
- 23- Bjørndal L. Indirect pulp therapy and stepwise excavation. *J Endod.* 2008 Jul;34(7 Suppl):S29-33.
- 24-Belobrov I, Parashos P. Treatment of tooth discoloration after the use of white mineral trioxide aggregate. *J Endod.* 2011 Jul; 37(7):1017-20.
- 25-Banava S, Fattah M, Kharazi Fard MJ, Safaie T, Askarzadeh S, Safaie Yazdi M, et al. [Clinical comparison of dental caries by DMFT and ICDAS systems.] *Islamic Dent Ass of IRAN. (JIDA) 2012 Summer; 24(2):176-83. (Persian)*
- 26-Monari V, Oliveira Lima Y, Rodrigues JA. Avoiding pulp exposure in deep caries lesions: Stepwise excavation technique. *RGO Rev Gaucha Odontol Porto Alegre.* 2011, 59;(4):633-38.
- 27-Banava S, Janfeshan Z, Saghiri M. [Invitro comparison of primary setting time and surface porosity in two brands of MTA.] *The J Islamic Dent Ass IRAN (JIDA).* 2012 Winter; 24(4):271-276. (Persian)
- 28-GC company. EQUIA brochure. 2013. Available: http://www.gcamerica.com/products/operatory/equia/GCA_EQUIA_Brochure.pdf, March08, 2013.
- 29-Banava S, Inanloo H, Ahoran M. [Antibacterial effect of new posterior glass ionomer cement (EQUIA System), resin modified glass ionomer, composite resin, and amalgam on streptococcus mutans and lactobacillus acidophilus in different times.] [Thesis]. Tehran: Azad Dental Faculty, Azad University; 2012. (Persian)