

Effects of Different Growth Factors on New Bone Formation: A Systematic Review

H. Behnia¹, A. Khojasteh^{2✉}, M. Esmaeelinejad³, N. Naghdi³

¹ Professor and Chairman, Department of Oral and Maxillofacial Surgery, School of Dentistry, Shahid Beheshti University of Medical Sciences, Tehran, Iran

² Assistant Professor, Department of Oral and Maxillofacial Surgery, School of Dentistry, Shahid Beheshti University of Medical Sciences AND Head of the Division of Basic Sciences, Dental Research Center, Tehran, Iran

³ Dental Student, Shahid Beheshti University of Medical Sciences, Tehran, Iran

Abstract

Background and Aim: Using different osteogenic growth factors, which is still under investigation, is a favorable method for bone regeneration. This systematic review is aimed at evaluating the effects of different growth factors and their carriers on osteogenesis.

Materials and Methods: Electronic databases (Medline, EMBase and Cochrane) were searched by the authors for articles published from 1999 to April 2010. Clinical and animal studies evaluating bone formation by applying a specific growth factor and the related carrier were included in this investigation. Obtained data were organized in a table and evaluated through a qualitative analysis.

Results: Sixty-three studies most of which evaluated the effects of BMP-2 osteogenesis in different models were included in this study. Totally, twenty-five carriers were applied with different growth factors in the experiments. Among these carriers, poly lactic-co glycolic acid (PLGA), hydroxy apatite/tricalcium phosphate/absorbable collagen sponge (HA/TCP/ACS) and BioOss were the most frequently used carriers with the growth factors in bone regeneration studies.

Conclusion: The current evidence, although not strong enough, confirms that BMP-2 has more favorable results in osteogenesis compared with other factors. The carrier scaffold, methods of measurement (histologic or radiographic), type of animal, defect diameter and the length of follow-up are the variables that should be matched before reaching definite results for the effect of growth factors in bone regeneration.

Key Words: Growth factors, Bone regeneration, New bone formation, Carrier, BMP

✉ **Corresponding author:**
Khojasteh A., Assistant Professor, Department of Oral and Maxillofacial Surgery, School of Dentistry, Shahid Beheshti University of Medical Sciences AND Head of the Division of Basic Sciences, Dental Research Center, Tehran, Iran
arashkhojasteh@gmail.com

Received: 2 March 2011

Accepted: 1 Dec 2011

Journal of Islamic Dental Association of IRAN (JIDAI) / Summer 2012 /24 / (3)

Introduction

Repair of fractured bones and regeneration of widespread osseous defects has become a challenge for orthopedists and maxillofacial surgeons in recent years [1], so that The United Nations Organization and World Health Organization have called years 2000 through 2010 as the decade of bones and joints [2]. Different mate-

rials and methods have been used for osseous regeneration (especially around implants) such as use of autogenous, allogeneous, and xenogeneous grafts as well as alloplastic materials, among which autogenous grafts are considered as the gold standard for osseous regeneration [3] However, use of such grafts have limitations such as lack of access to an appropriate graft tissue, pos-

sibility of transplant rejection, and high cost of the procedure which has led to development of other techniques for osseous regeneration [4,5]. Current literature has focused on three novel methods: transferring genes encoding osteogenic cytokines into the cells of the region (gene therapy); culturing the bone marrow stem cells of the patient and then implantation of osteogenic cells in the area of interest (stem cell-aided therapy); and use of osseous growth stimulation agents (protein therapy) [6]. The first two methods require especial considerations and widespread evaluations, the procedures are difficult and expensive [7]. In protein therapy which has the most laboratory and clinical evidence, osseous growth stimulation agents such as bone morphogenetic proteins (BMPs) [8,9], as well as other growth stimulation agents like vascular endothelial growth factor (VEGF) [10], platelet-derived growth factor (PDGF) [11] and transforming growth factor-beta-2 (TGF- β 2) [12] are used. Although BMPs are more extensively studied [13], other investigations show that use of other growth factors can have positive results providing new hopes in future. In addition, the synergistic effect of two or more growth factors are studied in a number of studies [14,15]. Since, the evaluated factors and their carriers are variable and studies are conducted differently, the obtained results are different and confusing to some extent.

The objective of this systematic review was to evaluate the effects of different growth factors in bone regeneration.

Materials and Methods

In this systematic review, the available literature was electronically searched within MedLine, EMBase and Cochrane Library databases. The searched articles were published from 1999 to April 2010. The key words by which the search was carried out contained words declaring bone formation such as *bone regeneration* OR *bone formation* OR *bone reconstruction*. Key words declaring growth factors (e.g. *osteogenic factor*

OR *growth factor*) were added with AND. Certain growth factors such as BMP, PDGF, VEGF and TGF were used as key words for a detailed search. All articles included in this review were written in English. (See table 1)

The inclusion criteria for the articles in this review were as follows:

- Publication years between 1999 to April 2010
- Articles published in English
- Clinical and original studies on human (clinical trials) or animal models (animal studies) with *in vivo* settings
- Articles concerning formation and growth of bone in correlation with a growth factor or a certain carrier.
- Studies investigating the effects of a certain growth factor on repair of experimentally induced bone defects

The exclusion criteria were as follows:

- In vitro* studies
- Reviews, letters and case reports
- Studies concerning success or failure of implants and osseointegration
- Studies evaluating the effect of a certain growth factor on repair of natural or pre-existing bony defects
- Non-randomized clinical trials
- Studies in which the evaluated factor differed in case and control groups.

Results

After selecting the articles according to the exclusion/inclusion criteria, various parts of each article including its primary information (such as the name of the journal, the publication year, and the authors' names), title, aim, methodology and results were separated to establish a single blind condition for the evaluator and to prevent bias towards a certain factor or a well-known author. Therefore, all possible attempts were done to prevent reviewer bias [8,9]. In each article the growth factor type, its carrier, the animal on which the study was performed, the site of the lesion, the evaluation time, the methodology of evaluation, the success rate, and the results were

extracted and organized in a table. At first, the key words were found. After reading the abstracts, data

Table 1: search strategy of articles according to the key words and inclusion/exclusion criteria relevant studies according to the inclusion criteria

Study steps	Procedure	Number of remaining articles
Step 1	Searching within Cochrane, EMBase, and PubMed databases	2868
Step 2	Omitting irrelevant articles	171
Step 3	Exclusion criteria in this step: 1. Non-randomized articles	95
	2. Evaluation of success/failure of implants and osseointegration	
Step 4	Exclusion criteria in this step: 1. In vitro designs	63
	2. Review articles, case reports and letters	
Step 5	Extracting identity information about articles	63
Step 6	Considering variables of growth factor, carrier, animal type, site of action, time of research, and success rate, and classifying these variables in a qualitative table	63
Step 7	Registration of bone regeneration based on bone reconstruction(%), height of reconstructed bone (mm), amount of bone reconstruction radiographically (%), bone density (g/mm^3), and the volume of reconstructed bone	63
Step 8	Comparison of articles with equal conditions, evaluation of the effects of contributing factors and related carriers in bone regeneration	63
Step 9	Conclusion	63

ganized in a comprehensive table. Then, variables including the growth factor, carrier, animal type, site of effect, study time, and success rate were classified in a new table in order to perform a qualitative evaluation. The amount of new bone formation in these studies had been evaluated radiographically or histomorphometrically. Bone regeneration and the amount of bone formation had been described as bone minerals density (BMD), percentage of new bone formation or new bone volume or height. (See table 2) Comparisons were carried out to declare a concise conclusion out of the studies which were designed under relatively equal circumstances. Superiority of a certain factor or carrier was depicted based upon abundance of studies or significance of results. Studies in which comparison of the effects of two or more factors or carriers were used to evaluate the factor with a more significant effect.

Results

In the primary search, 171 articles related to the

ria were determined. Among the total articles found, 63 articles were included in the project. (fig. 1) According to the available evidence, it seems that BMP-2 possesses the highest capability for differentiation of mesenchymal cells into osteoblasts among all bone morphogenetic proteins. This has made BMP-2 at the center of attraction for researchers in comparison with other factors [1, 13]. Thoroughly, 11 different evaluations have been carried out concerning the effect of BMP-2 in formation of new bone with different carriers. This factor has been most frequently utilized with gelatin hydrogel and hyaluronic acid. The bone morphogenetic protein which is produced via recombinant DNA (rhBMP) is considered as one of the growth factors with bone inductive activity [25]. Application of this growth factor accompanied by an appropriate carrier such as absorbable collagen sponge (ACS) provides a proper bed for migration, proliferation, and differentiation of bone

Table 2: Qualitative data resulting from evaluation of articles

Growth factor	Article	carrier	Evaluation time/ defect location/ animal type	Evaluation technique	The obtained results
BMP-2	<i>Yamamoto M. et al (2006)(30)</i>	Gelatin Hydrogel	Rabbit/Ulna/6	Histology and Radiography	Increased bone density in gelatin hydrogel with 97.8% water was significantly more than other types of gelatin hydrogel (with different vol% water)
	<i>Takahashi Y. et al(2006) (29)</i>	Gelatin Hydrogel	Monkey/Parietal/12	Radiography and Histology	Bone density increased with increased concentration of BMP-2 in the gelatin carrier
	<i>Chung Y. et al (2007)(44)</i>	Nanoparticle-hydrogel complex/Fibrin gel	Rat/Cranium/4	Radiography and Histology	Bone reconstruction was enhanced by BMP-2. However, use of the considered carrier resulted in bone formation with improved mineralization and development
	<i>Tien-Min G. Chu et al(2007) (33)</i>	Dicalcium phosphate dehydrate	Rat/Femur/6	Radiography and Histology	After weeks 6,12, and 15, the results of radiographic evaluation were considerably better for BMP-2 compared with other groups, which shows the influence of this factor in better osseous reconstruction.
	<i>Samee M. et al(2008) (36)</i>	β -TCP ^a	Rat/Thigh muscle/8	Histology	Ectopic bone was seen in all areas after 4 weeks and was considerably increased after 8 weeks.
	<i>Aghaloo T. et al(2010) (21)</i>	PLGA	Rat/Calvarium/8	Live micro-CT	After 4 weeks, 90% of lesions were replaced by bone. This amount approximated to 100% with time.
	<i>Young S. et al(2009) (14)</i>	Gelatin microparticles/ Poly(propylene fumarate)	Rat/ Calvarium /	Histomorphometry and micro-CT	According to the concentration of BMP-2, bone reconstruction was at least 6% and at most 19.5%. Eight weeks following implantation of the samples, using 5 to 20mg BMP, complete bone reconstruction was observed in all cases. In addition, using the considered carrier resulted in a 1/10 decrease in amount of the required BMP.
	<i>Kaito T. et al (2005) (45)</i>	IPCHA ^b + PLA-PEG ^c	Rabbit/Radius/8	Radiography, Histology, micro-CT and mechanical compression test	
	<i>Arosarena O.A. et al(2004) (22)</i>	HA ^d Or HA/TCP/ACS ^e	Rat/Mandible/	Histology	Bone regeneration and growth were considerably more in samples containing BMP-2. However, there was not a significant difference between the formed osteoid and the estimated volume in experimental samples.
	<i>Arosarena O. et al(2005) (31)</i>	Hyaluronic acid	Rat/Mandile/	Histology	The volume of the constructed bone increased with an increase in BMP-2, although statistically non-significant.
<i>Kim J. et al (2007) (32)</i>	Acrylated hyaluronic acid	Rat/Calvarium/4	Histology	Histologic evaluations showed that use of hydrogels accompanied with BMP-2 and MSCs caused maximal expression of osteocalcin and developed bone in comparison with other groups.	

BMP-2	<i>Asamura S. et al(2010) (46)</i>	Gelatin Hydrogel	Dog/ Canine orbital floor fracture/5	Histomorphometry	Trabecular bone volume was quite less in samples without gelatin carrier than those with carrier.
	<i>Sawada Y. et al(2009) (41)</i>	Gelatin Hydrogel	Rabbit/Maxilla/4	Histology and micro-CT	Bone regeneration in samples with growth factor and gelatin hydrogel carrier was quite more than other samples.
	<i>Smeets R. et al(2009) (47)</i>	Calcium phosphate	Dog/Buccal alveolar defects /16	Radiofrequency analysis and Histomorphometry	No significant statistical difference was seen between experimental and control groups
	<i>Kokubo S et al (2003) (17)</i>	PLGA-coated gelatin sponge	Rabbit/Ulna/16	Radiography and Histology Biomechanical evaluation	Longitudinal growth of lamellar bone after 16 weeks conveyed the complete bone regeneration.
	<i>Marukawa E. et al(2001) (18)</i>	PLGA	Monkey/Mandible/12	Radiography and Histology	The new bone was a combination of woven and lamellar bones. The amount of lamellar bone increased after 12 weeks. The thickness of trabecular bone was significantly increased in comparison with the 6 th week.
	<i>Matin K. et al(2003) (20)</i>	PLGA	Rat/Maxilla/12	Microscopic analysis	In experimental group, new bone covered all coronal parts of implants. New bone had a smooth surface with osteocytic lacunae creating an appearance similar to that of alveolar bone.
	<i>Miranda D et al(2005) (23)</i>	ACS/HA/TCP	Monkey/Jaws/16	Histomorphometry	Transverse bone reconstruction in groups with rhBMP-2 was significantly more than that in other groups. There was no significant difference in using TCP/HA/ACS or a-BSM as carriers.
	<i>Cochran D.L. et al(2000) (28)</i>	ACS	Human/Alveolar ridge/54	Radiography and Histology	The amount and thickness of trabecular bone in both apical and coronal aspects increased in a moderate to high degree. The amount of the woven bone was quite variable.
	<i>Carstens M.H. et al(2005) (24)</i>	ACS	Pig/Mandible/12	Radiography and Histology	Bone regeneration was observed unevenly after 60 days. Complete bone regeneration was seen after 90 days
	<i>Jovanovic S.H. et al(2006) (25)</i>	ACS	Dog/Mandible/12	Radiography and Histology	Complete bone regeneration was seen in histologic and radiographic evaluations.
	<i>WikesjoU. et al (2004) (26)</i>	ACS	Dog/Jaws/8	Radiography and Histology	Bone regeneration in the group with the growth factor and ACS carrier was much more than in control group. Histologic evaluation declared complete bone reconstruction in the experimental group.
	<i>Tatakis DN et al (2002) (48)</i>	ACS	Dog/Jaws/8	Radiography and Histology	A significant increase was observed in density and structure of trabecular bone between the 6 th and 8 th weeks. However a decrease in bone volume and height was also observed. Histometric evaluation revealed a minute difference between control and experimental groups.

	<i>Sykaras N. et al (2000) (49)</i>	Bovine collagen	Dog/Jaws/12	Radiography and Histology	There was no significant difference between experimental and control groups.
	<i>Jung R.E et al (2002) (27)</i>	Bio-Oss	Human/Jaws/4	Histomorphometry	The decrease from the baseline in height of the bony defect in both control and experimental groups was statistically significant.
	<i>Jung R.E. et al (2009) (50)</i>	graft material and the collagen membrane	Human/Jaws/3 to 5 years	Clinical evaluation and Radiography	No statistically significant difference in implants was observed experimental and control groups.
	<i>Chen B, et al (2007) (51)</i>	DBM ^f	Rabbit/Mandible/12	Histomorphometry	Partial and inadequate reconstruction of bone was seen in control group whereas more bone with a higher quality was observed in rhBMP2-h/DBM group.
	<i>Samee M. et al(2008) (36)</i>	β -TCP ^a	Rat/Thigh muscle/8	Histology	Ectopic bone was seen in all areas after 4 weeks and was considerably increased after 8 weeks.
PDGF	<i>Hokugo A. et al(2007) (37)</i>	Gelatin Hydrogel	Rabbit/Calvarium/8	Histology and micro-CT	Use of gelatin hydrogel and PRP in combination with the considered factor resulted in a complete bone regeneration in the area.
	<i>MarzoukKh. et al (2008) (40)</i>	Vinyl styrene microbeads	Rat/Calvarium/	Histomorphometry	Use of the considered carrier to transfer the osteoblastic progenitors caused a significant increase in new bone volume.
rhPDGF	<i>Schwarz F. et al(2009) (52)</i>	Natural bone mineral(NBM)/Collagen membrane	Dog/Mandible/3	Histomorphometry	Formation of even trabecular bone in both coronal and central directions was observed and was initiated primarily around NBM.
	<i>Nevins M. et al (2003) (53)</i>	DFDBA ^g Or ABB-C ^h	Human/Jaws/12	Histology and Radiography	Histologic evaluation revealed a complete regeneration of periodontal apparatus including cementum, PDL, and bone in furcation involvement are.
	<i>Schwarz F. et al (2009) (54)</i>	BCP ⁱ /CM ^j	Dog/Mandible/	Histomorphometry	Level of regeneration as well as the amount of mineralization was significantly more in experimental than control groups.
VEGF	<i>Yonamine Y. et al(2010) (55)</i>	PLGA	Rat/Calvarium/12	Radiography	VEGF microspheres with PLGA membranes caused a significant increase in bone reconstruction compared with other groups.
	<i>Kleinheinz J. et al(2005) (35)</i>	Collagen type 1 matrix	Rabbit/Mandible/4	Histology	There was an observable amount of bone formation in experimental group but its difference with the control group was not statistically significant.
	<i>Samee M. et al(2008) (36)</i>	β -TCP	Rat/ Thigh muscle/8	Histology	Bone regeneration in VEGF/BMP-2 group was significantly more than other groups in days 21c and 28, but there was no significant difference between VEGF and the control group.

	<i>Leach J.K. et al (2006) (10)</i>	Polymeric scaffolds with a bioactive glass coating	Rat/Calvarium/12	micro-CT	The carrier containing VEGF caused a significant increase in bone density with respect to control groups.
	<i>Wernike E. et al (2010) (56)</i>	Biphasic calcium phosphate	Rat/Calvarium/4	Histomorphometry	Superficial absorption of VEGF was not influential in bone formation.
PDGF/VEGF	<i>De la Riva B. et al(2009) (11)</i>	Brushite–chitosan	Rabbit/Femur/4	Histomorphometry	The carrier containing PDGF caused a significant increase in bone regeneration. Also, combined use of PDGF/VEGF enhanced bone reconstruction
bFGF	<i>Niedhart C. et al(2001) (57)</i>	β -TCP	Rat/Femur/3	Histomorphometry	There was no statistically significant difference between experimental and control groups.
	<i>Akagawa Y. et al(2010) (58)</i>	Gelatin Hydrogel	Dog/Mandible/4	Histomorphometry	The height of regenerated bone was higher in the group with a concentration of 10 micrograms and 95 volume percent of gelatin hydrogel.
	<i>Yuan Q. et al (2008) (59)</i>	Inorganic polyphosphate	Rabbit/Femur/3	Histomorphometry	Simultaneous use of bFGF and the considered carrier resulted in stimulation of cellular proliferation and increased bone mineralization.
	<i>Murakami S. et al (2003) (60)</i>	Gelatinous carrier	Dog/Mandible/6	Histomorphometry	The amount of new bone formation, new trabecular bone formation and new cementum regeneration was significantly higher in samples with bFGF compared with controls.
FGF-2	<i>Ichinohe N. et al (2008) (61)</i>	Gelatin Hydrogel(GM)+titanium nonwoven fabrics(Ti)	Rabbit/Calvarium/	Histomorphometry	Amount of bone regeneration in Ti-HA-GM was significantly higher than Ti, Ti-HA, and Ti-HA+FGF-2 groups.
	<i>Kitamura M. et al (2008) (62)</i>	Hydroxypropylcellulose	Human/Jaws/36	Clinical evaluation and Radiography	Rate of alveolar bone height increase in experimental group was significantly higher than that in control group.
PRGF	<i>Fuerst G et al(2004) (38)</i>	Collagen type 1	Pig/Mandible/	Collagen type 1	There was no significant difference between (collagen I + PRP) and (collagen only) groups and between (collagenI+PRGF) and (control) groups. However, the difference between (collagen) group and (control) was statistically significant.
TGF-β3	<i>Maissen O. et al(2006) (16)</i>	PLGA	Sheep/Tibia/12	Radiography and CT	Marginal hardness of bone in (bone graft) group was significantly more than those of (PLA/rhTGF β -3) and (PLA) groups. Also, radiographic evaluation revealed a significant difference between the bone graft group and other two groups.
	<i>Ripamonti U. et al (2009) (64)</i>	Matrigel matrix	Monkey/Mandible/	Histomorphometry	Alveolar bone regeneration and cementum formation in furcation defects are positively related to the concentration of TGF- β 3 of matrigel matrix.

rhTGF-β1	<i>Ehrhart N.P et al (2004) (39)</i>	Gelatin Hydrogel	Rabbit/Ulna/4	Radiography and Histomorphometry	New bone formation in experimental defects (containing factor) was significantly more than control(carrier only).
BMP-2/VEGF	<i>Kanczler J.M. et al(2009) (15)</i>	PLGA/Alginate	Rat/Femur/	Histology and micro-CT	Volume of new bone in Alginate-VEGF165/PDLLA-BMP-2 + HBMSC group was significantly more than that in Alginate/PDLA group and Alginate-VEGF165/PDLA-BMP-2 group.
	<i>Kempen D. et al(2008) (19)</i>	PLGA	Rat/Femur/8	Histomorphometry and micro-CT	Although VEGF did not stimulate bone formation, it was able to enhance formation of a supporting vascular plexus. Simultaneous release of VEGF and BMP-2 in an ectopic area improved bone regeneration and provided better results than the use of BMP-2 alone.
	<i>Young S. et al (2008) (14)</i>	Poly(propylene fumarate)/Gelatin microparticle	Rat/Calvarium/12	Histomorphometry and micro-CT	Percentage of bone regeneration was related to the amount of BMP-2. In this certain model simultaneous release of BMP-2 and VEGF was not significantly influential and bone regeneration was not more than that of BMP-2 only group.
	<i>Patel Z. et al(2008) (42)</i>	Poly(propylene fumarate)/Gelatin micro particle	Rat/Calvarium/12	Histomorphometry and micro-CT	Addition of VEGF to BMP-2 did not have a significant effect on the regenerated bone, but could help in homogeneity and integrity of the new bone.
rhGDF-5	<i>Gruber R.M. et al (2007) (64)</i>	β -TCP	Pig/Maxilla/4	Histomorphometry	After 4 weeks, new bone density in a group with TCP carrier concentration of 400mg/g was more than control.
	<i>Weng D. et al (2008) (65)</i>	β -TCP	Dog/Mandible/	Histomorphometry	Although there was no significant difference between the experimental and control group, samples containing GDF tend to indicate more bone formation.
	<i>Kim T. et al (2009) (66)</i>	ACS	Dog/Mandible/	Histomorphometry	There was no significant difference between experimental and control groups in the amounts used in this experiment.
rhGDF-5 or rhBMP-2	<i>Schwarz F. et al(2009) (67)</i>	Natural bone mineral(NBM)	Rat/Calvarium/24	Histomorphometry	Mineralized tissue content in rhBMP-2 +NBM+ collagen membrane group was significantly more than that in other groups.
BMP-2/TGF-β2	<i>Canter H.I . et al (2010) (44)</i>	Chitosan Gel Matrix	Rat/Calvarium/14	Radiography and Histomorphometry	Combined use of TGF-2 and BMP-2 did not have a significant effect on bone regeneration compared with the use of BMP-2 only and the synergistic effect of these two factors is insignificant.
CCN-2	<i>Kikuchi T. et al (2007) (68)</i>	Gelatin Hydrogel /Collagen sponge	Rat/Femur/2	Histology	Use of CCN2 accompanied with gelatin carrierand collagen sponge had a significant effect on stimulation of bone mineralization.

PDGF/
TGF-β1/
IGF-1/
VEGF/
EGF

Moder Ch.M.
et al (2006) (69)

Bioresorbable guided tissue
regeneration-membrane/
β-TCP

Human/Jaws/51

Radiography

Although there was a slight predilection for better bone regeneration following 3 and 6 months (positive median values) and this predilection to regeneration is corroborated after 12 months (negative median values), the data were quite inconstant and no significant superiority was attributable to any of the methods

- a-tricalcium phosphate
- b-interconnected-porous calcium hydroxyapatite ceramics
- c-poly D,L,-lactic acid–polyethyleneglycol block co-polymer
- d-hydroxy apatite
- e-absorbable collagen sponge
- f-demineralized bone matrix
- g-demineralizedfreez dried bone allograft
- h-anorganic bovine bone in collagen
- i-biphasic calcium phosphate
- j-collagen membrane

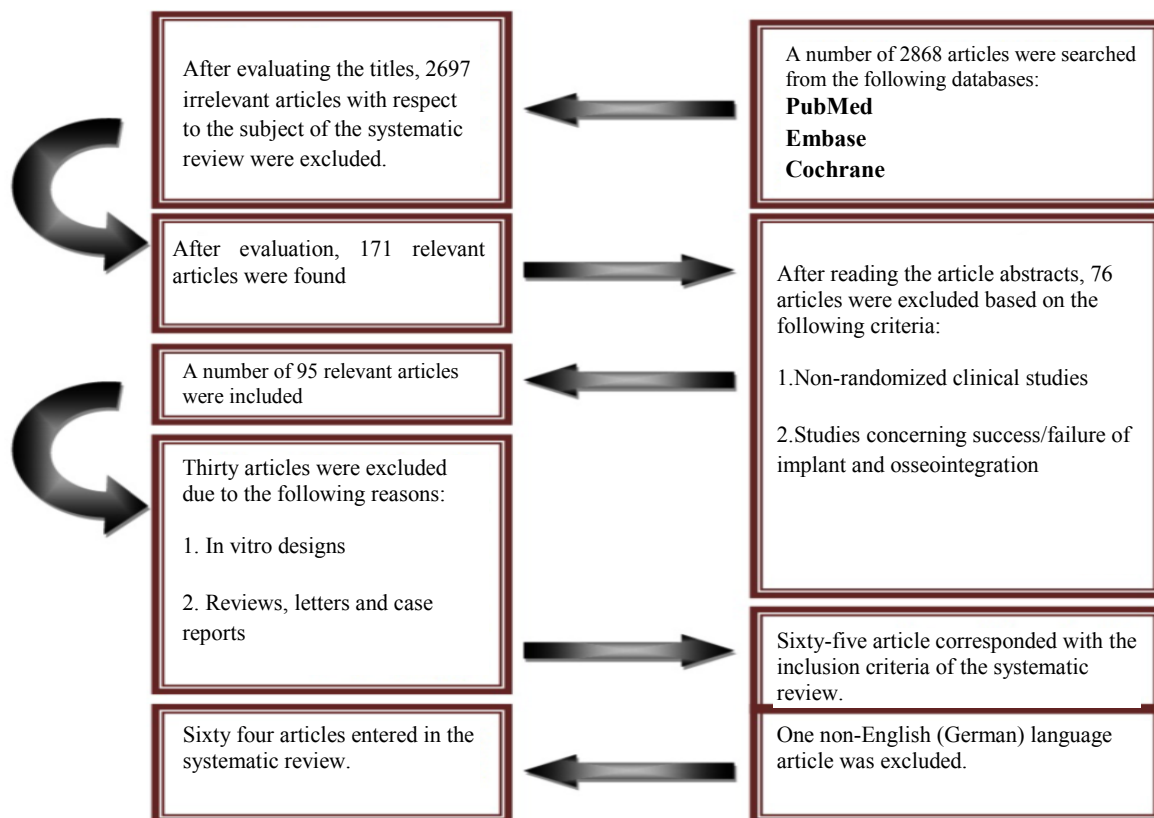


Figure 1: stages of accessibility to the articles

marrow stem cells [24]. Numerous articles taken into consideration in the current investigation (n=16) have focused on this factor. In the majority of these articles this factor had been used with ACS (n=5) and polylactic co-glycolic acid (PLGA) (n=2). Growth and differentiation factor 5 (GDF-5) is a member of morphogenetic proteins family and is also known as BMP-14. [64] Osteogenic potency of the recombinant form of this factor (rhGDF-5) was evaluated in four studies two of which used β -tricalcium phosphate (β -TCP) as the carrier. Fibroblast growth factors (FGFs) are a group of proteins that have a crucial role in cellular proliferation, angiogenesis, and fibroblast differentiation. Totally, six studies have been performed on different types of FGFs, each using different carriers. Platelet-derived growth factor (PDGF) have been used in five different studies, each using different carriers. Vascular endothelial growth factor (VEGF) is considered an angiogenic factor and is increased in response to hypoxia, ischemia, as well as tissue regeneration and repair. Totally, there were ten studies evaluating the role of VEGF in bone reconstruction, among which five studies evaluated the effect of VEGF per se on bone reconstruction. In four other studies, the combined effect of VEGF and BMP-2 and in the remaining study the simultaneous effect of VEGF and PDGF was evaluated. Plasma rich growth factor (PRGF) was used only in one study accompanied with collagen type I as the carrier and caused no significant difference in bone reconstruction. TGF- β , one of the important growth factors in bone formation, was evaluated in three studies for its effect on marginal bone reconstruction. In all of the evaluated articles 25 carriers were used accompanied with growth factors, among which 11 carriers were more extensively studied. Out of these 11 carriers, three had considerable effects on bone reconstruction, which are described as follows:

1. Polylactic co-glycolic acid (PLGA) [16-21].

This material was used as carrier in seven studies. The highest amount of bone reconstruction

has been reported to be with the use of rhBMP-2. Use of this carrier in combination with an appropriate factor has led to about 65% increase in new bone formation.

2. Simultaneous use of hydroxyapatite/tricalcium phosphate/absorbable gelatin sponge (HA/TCP / ACS) [22]

Use of this carrier in combination with an appropriate growth factor can help increase bone minerals density (BMD) to about 80%. In both studies in which this carrier was used with rh-BMP-2 or BMP-2, a considerable volume of bony defects were reconstructed by new bone.

3. BioOSS [23]

The effect of rhBMP-2 with the use of this carrier was studied in only one article, concluding that this carrier was able to increase bone volume to 58.5% in case it is used with an appropriate growth factor.

4. Absorbable collagen sponge (ACS)

[24-26, 28,48,66]

ACS was used in six studies mainly with rhBMP-2 (in five studies). In most studies in which this carrier was used with rhBMP-2, favorable results have been achieved in bone regeneration.

5. Gelatin/ hydrogel [29,30,37,39,41,46,58,60,68]

Gelatin hydrogel is one of the most frequently used carrier agents which had been used in nine studies alone or in combination with other materials. In general, use of this carrier with a large number of other factors have shown relatively promising results. But, in many studies the results have shown that the volume percent of water in gelatin hydrogel can play a crucial role in the amount of bone regeneration.

6. Hydroxyapatite (HA) [22]

Hydroxyapatite has rarely been used alone in the studies. It has been most frequently used with other agents such as absorbable collagen sponge and tri-calcium phosphate.

7. Hyaluronic acid [31,32]

Hyaluronic acid had only been used in only two studies as a carrier with BMP-2. The number of

studies in this regard is scarce and therefore not documentable enough.

8. Natural bone matrix (NBM) [52,67]

In two separate studies, this carrier was used with rhPDGF and rhGDF-5. In these two studies the initiation of bone formation was found to be around NBM.

9. Demineralized bone matrix (DBM) [51]

DBM was used in only in one study with rh-BMP-2. Use of this carrier with rh-BMP-2 gave rise to better results in bone reconstruction in comparison with the control group, but such difference was not statistically significant.

10. Collagen [35,38,49,68]

Collagen was used in four separate studies with rh-BMP-2, rhPDGF, PRGF, or VEGF.

11. Beta tri-calcium phosphate (β -TCP)

[36,57,64,65,69]

β -TCP was used in five studies but not with promising results in all of them. Qualitative results of the evaluated articles are represented and classified in table 1.

Discussion

Bone morphogenetic proteins (BMPs) comprise a superfamily of inductive agents for growth and development that are found in different tissues such as cartilage, bone, and even myocardium [29,30]. Several studies have declared that use of this agent with PLGA carrier had a significant effect in new bone formation [19,21]. In other studies, simultaneous use of this agent with a gelatin hydrogel carrier [29,30] and hyaluronic acid [31,32] has been proved to increase bone minerals density (BMD) and construct new bone. In fact, numerous studies have confirmed the effect of this factor in bone regeneration using radiographic or tomographic methods [19,33]. Allegrini et al conducted a study on the effect of BMP-2 in sinus lifting of rabbits in 2003 in Brazil. They demonstrated that use of this factor with hydroxyapatite increased rate of bone formation to 7.12%. Further electron microscopic evaluations revealed that the highest growth rate occurred in days 21 and 24 in expe-

perimental and in days 21 and 28 in control group. [34] The positive effect of rh-BMP-2 and the collagen carrier in new bone formation and increased bone density is well understood [24-26]. Kokubo and colleagues evaluated the effect of rh-BMP-2 with PLGA on bone regeneration in 2003. In this investigation bone formation was evaluated in defects induced in diaphysis of ulnar bones in rabbits. It was demonstrated by radiographic pOCT method that the radiographic union rate was 100% for the new bones after 16 weeks. Biomechanical test disclosed that the maximal torque of the experimental group was 75.6% that of healthy bone showing a significant difference with the control group [17]. The most pronounced effect of rhBMP was observed on bone minerals density, whereas BMP-2 had a significant effect on the amount of bone formation. (Bone formation was more than other factors based on histomorphometric evaluations of similar investigations.) Equivalent evaluations revealed that the effect of rhBMP-2 is not at the level of BMP-2, but still is acceptable. Regarding the available literature, rhBMP-2 is not significantly effective in promoting longitudinal bone formation. The inadequate number of article failed to provide a documentable evidence for other factors. Therefore the obtained results failed to have a comparative value. One of the members of BMP superfamily is rhGDF-5 which I also known as BMP-14 [64]. Studies declare that use of rhGDF-5 alone could not have a significant effect on bone regeneration [65-67]. However, Gruber et al demonstrated that combination of this factor with β -TCP could significantly increase the amount of bone formation [64]. This signifies the importance of agent used as carrier. Some carrier agents such as β -TCP and BioOss have some chemical properties in common with those of bone. use of these materials can provide an organized bed for bone regeneration. On the other hand, such materials are not resorbed during remodeling process and there is a possibility for them to delay osseous regeneration. Taking this into consideration, use

of resorbable carriers such as ACS is justifiable. Hence, a large number of included studies used this material as a carrier for rhBMP-2 with promising results [24-26, 28,48]. Schwarz and co-workers in 2009 compared rhGDF-5 and rhBMP-2 in reconstruction of bony defects on murine cranium. They concluded that the ability of rhBMP-2 in bone regeneration was significantly more than that of rhGDF-5 [67]. FGFs are proteins that have a crucial role in cellular proliferation and fibroblast differentiation. Generally, according to the results of the studies, the role of FGF in promoting bone regeneration is not well understood. A number of studies disclosed the effective role of this factor in osteogenesis. [58-60,62], whereas other studies revealed contradictory results [57, 61] Nevertheless, one has to bear in mind that such difference can be due to the use of different carrier materials. Hence, more extensive studies are required to obtain more accurate results in this regard. Some studies have focused on the effect of angiogenic factors such as VEGF [35,36], PDGF [37,38], and TGF- β [16,39] on bone regeneration. These factors are assumed to have a role in new bone formation due to their potential in angiogenesis. Although adequate blood supply is a prerequisite for anabolic activity of bone cells, these factors are not significantly effective in the process of osseous regeneration. PDGF is one of the growth factors used in bone regeneration. Its mode of action is still a matter of debate for the authors. [40] Carrier agents used with PDGF are not uniform in any of the articles [40,52-54]. Indicating inadequate information about application of this growth factor. PDGF-BB is one of the members of this family with the highest mitogenic and chemotactic activity [37,40]. It is presumed that members of this family cause an increase in formation of osteopontin and a decrease in production of osteocalcin [40]. Although, positive effects of these factors including rhPDGF in reconstruction of periodontal and alveolar bone defects is proposed by some [40,52-54], it is suggested that cellular and molecular investiga-

tions be conducted to confirm its mode of action. Platelet-rich plasma (PRP) is also one of the agents used to regenerate bone. In order to produce plasma-rich growth factor, cells in plasma are activated by thrombin and then centrifuged. Then PRGF is derived from the supernatant. This factor causes an increase in proliferation of bone cells and fibroblasts [38]. Nonetheless, adequate findings to conclude about the added effects of this agent in new bone formation compared with factors is still lacking emphasizing on the need for further investigations. TGF- β is an important growth factor in bone formation. The considerable potential for the members of this family to induce new bone formation has led to the widespread use of these factors in osseous reconstruction. Bone morphogenetic proteins are important members of this superfamily which were previously discussed. TGF- β 1 and rhTGF- β 3 are other members presumed to have the ability to stimulate osteoblast proliferation and extracellular matrix formation [16,64]. Use of TGF- β 1 with gelatin hydrogel has led to promising results [39]. However, in order to obtain more favorable results, there is a continuous emphasis on its use with one of BMP family members [70]. Vascular endothelial growth factor (VEGF) is another angiogenic factor that is increased in response to hypoxia, ischemia, repair, and tissue regeneration. Studies demonstrate that VEGGF increases the repair rate of tissues, but its use alone does not have a significant role in enhancing bone formation and mineralization [29,56]. Probably, the most controversial results are related to the simultaneous use of VEGF and BMP-2. Samee and coworkers evaluated the role of this factor with β -TCP carrier in ectopic bone formation in muscles of the murine foot. The results indicated that the amount of bone formation was significantly higher in VEGF/BMP-2 group in days 21 and 28 compared with other groups. On the other hand, no significant difference was found between VEGF group and controls [29]. In 2009, Patel et al evaluated the combined effect of VEGF/BMP-2 in

reconstruction of cranial defects in mice. They concluded that addition of VEGF to BMP-2 did not significantly affect the amount of regenerated bone, but could help in homogeneity and integrity of the bone [42]. These two studies and other investigations [14,15,19], are indicative of ambiguity in application of VEGF. In fact, this can be attributable to the carrier with which VEGF is used. All studies using PLGA as a carrier demonstrated significant results from simultaneous application of VEGF and BMP-2 [15,19], but in other studies the results failed to show a statistical significance. This can declare the importance of carrier in the growth factor's mode of action [14,42]

Conclusion

The available evidence, although feeble, could demonstrate the stronger effect of BMP-2 and rhBMP-2 in the process of bone formation and regeneration. It should be borne in mind that suspicions exist concerning application of other growth factors including angiogenic factors. In all cases, appropriate carriers are required for releasing and transferring growth factors due to their short half-lives. Amongst all carrier agents, gelatin hydrogel has been of widespread acceptance indicating relatively promising results when used with some growth factors. On the other hand, it appears that simultaneous use of the three carriers ACS, HA, and TCP can be influential in better transfer of the growth factor and improved bone regeneration. In general, regarding the numerous and widespread studies performed and the differences between them, as well as the use of variable carriers and few available evaluations on most of the factors, it is impossible to issue a conclusion with certainty or introduce a certain carrier or factor as the best in this regard.

References

- 1-Haidar ZS, Hamdy RC, Tabrizian M. Delivery of recombinant bone morphogenetic proteins for bone regeneration and repair. Part A: Current challenges in BMP Delivery. *Biotechnol Lett.* 2009 Dec; 31(12):1817-24.
- 2-Weinstein SL. The Bone and Joint Decade. *J Bone Joint Surg Am.* 2000 Jan; 82(1):1-3.
- 3-Block MS, Kent JN. Sinus augmentation for dental implants: the use of autogenous bone. *J Oral Maxillofac Surg.* 1997 Nov; 55(11):1281-6.
- 4-Geiger M, Li RH, Friess W. Collagen sponges for bone regeneration with rh-BMP-2. *Adv Drug Deliv Rev.* 2003 Nov 28; 55(12):1613-29.
- 5-Bishop GB, Einhorn TA. Current and future clinical application of bone morphogenetic proteins in orthopedic trauma surgery. *Int Orthop.* 2007 Dec; 31(6):721-7.
- 6-Rose FR, Hou Q, Oreffo RO. Delivery systems for bone growth factors- the new players in skeletal regenerations. *J Pharm Pharmacol.* 2004 Apr; 56(4):415-27.
- 7-Kimelman N, Palled G, Helm GA, Huard J, Schwarz EM, Gazit D. Review: Gene and stem cell-based therapeutics for bone regeneration and repair. *Tissue Eng.* 2007 Jun; 13(6):1135-50.
- 8-Moore YR, Dickinson DP, Wikesjö UME. Growth/differentiation factor-5: A candidate therapeutic agent for periodontal regeneration? A review of pre-clinical data. *J Clin Periodontol* 2010 Nov; 37(3):288-298.
- 9-Bessa PC, Casal M, Reis RL. Bone morphogenetic proteins in tissue engineering: the road from the laboratory to the clinic, part I (basic concepts). *J Tissue Eng Regen Med.* 2008 Jan; 2(1):1-13.
- 10-Leach JK, Kaigler D, Wang Zh, Krebsbach PH, Mooney DJ. Coating of VEGF-releasing scaffolds with bioactive glass for angiogenesis and bone regeneration. *Biomaterials.* 2006 Jun; 27(17):3249-55.
- 11-De la Riva B, Sanchez E, Hernandez A, Reyes R, Tamimi F, López-Cabarcos E, et al. Local controlled release of VEGF and PDGF from a combined brushite-chitosan system enhances bone regeneration. *J Control Release.* 2010 Apr 2; 143(1):45-52.
- 12-Yamamoto M, Tabata Y, Hang L, Miyamoto S, Hashimoto N, Ikeda Y. Bone regeneration by

- transforming growth factor B1 released from a biodegradable hydrogel. *J Control Release*. 2000 Feb 14; 64(1-3):133-42.
- 13-Vaccaro AR, Whang PG, Patel T, Phillips FM, Anderson DG, Albert TJ, et al. The safety and efficacy of OP-1 (rhBMP-7) as a replacement for iliac crest autograft for posterolateral lumbar arthrodesis: Minimum 4-year follow-up of a pilot study. *Spine J*. 2008 May-Jun; 8(3): 457-65.
- 14-Young S, Patel ZS, Kretlow JD, Murphy MB, Mountziaris PM, Baggett LS, et al. Dose effect of dual delivery of vascular endothelial growth factor and bone morphogenetic protein-2 on bone regeneration in a rat critical-size defect model. *Tissue Eng Part A*. 2009 Sep; 15(9): 2347-62.
- 15-Kanczler JM, Ginty PJ, White L, Clarke NM, Howdle SM, Shakesheff KM, et al. The effect of the delivery of vascular endothelial growth factor and bone morphogenetic protein-2 to osteoprogenitor cell populations on bone formation. *Biomaterials* 2010 Feb; 31(6):1242-50.
- 16-Maissen O, Eckhardt C, Gogolewski S, Glatt M, Arvinte T, Steiner A, et al. Mechanical and radiological assessment of the influence of rhTGF β -3 on bone regeneration in a segmental defect in the ovine tibia: Pilot Study. *J Orthop Res*. 2006 Aug; 24(8):1670-8.
- 17-Kokubo S, Fujimoto R, Yokota S, Fukushima S, Nozaki K, Takahashi K, et al. Bone regeneration by recombinant human bone morphogenetic protein-2 and a novel biodegradable carrier in a rabbit ulnar defect model. *Biomaterials* 2003 Apr; 24(9):1643-51.
- 18-Marukawa E, Asahina I, Oda M, Seto I, Alam MI, Enomoto S. Bone regeneration using recombinant human bone morphogenetic protein-2 (rhBMP-2) in alveolar defects of primate mandibles. *Br J Oral Maxillofac Surg*. 2001 Dec; 39(6):452-9.
- 19-Kempen DH, Lu L, Heijink A, Hefferan TE, Creemers LB, Maran A, et al. Effect of local sequential VEGF and BMP-2 delivery on ectopic and orthotopic bone regeneration. *Biomaterials* 2009 May; 30(14):2816-25.
- 20-Matin K, Senpuku H, Hanada N, Ozawa H, Ejiri S. Bone regeneration by recombinant human bone morphogenetic protein-2 around immediate implants: A Pilot Study in Rats. *Int J Oral Maxillofac Implants*. 2003 Mar-Apr; 18(2): 211-7.
- 21-Aghaloo T, Cowan CM, Zhang X, Freymiller E, Soo C, Wu B, et al. The Effect of NELL1 and Bone Morphogenetic Protein-2 on Calvarial Bone Regeneration. *J Oral Maxillofac Surg*. 2010 Feb; 68(2):300-8.
- 22-Arosarena O, Collins W. Bone regeneration in the rat mandible with bone morphogenetic protein-2: A comparison of two carriers. *Otolaryngol Head Neck Surg*. 2005 Apr; 132(4):592-7.
- 23-Miranda DA, Blumenthal NM, Sorensen RG, Wozney JM, Wikesjo UM. Evaluation of recombinant human bone morphogenetic protein-2 on the repair of alveolar ridge defects in baboons. *J Periodontol*. 2005 Feb; 76(2):210-20.
- 24-Carstens MH, Chin M, Li J. In Situ Osteogenesis: Regeneration of 10-cm mandibular defect in porcine model using recombinant human bone morphogenetic protein-2 (rhBMP-2) and helistat absorbable collagen sponge. *J Craniofac Surg*. 2005 Nov; 16(6):1033-42.
- 25-Jovanovic SA, Hunt DR, Bernard GW, Spiekermann H, Wozney JM, Wikesjo UM. Bone reconstruction following implantation of rhBMP-2 and guided bone regeneration in canine alveolar ridge defects. *Clin Oral Implants Res*. 2007 Apr; 18(2):224-30.
- 26-Wikesjö UM, Qahash M, Thomson RC, Cook AD, Rohrer MD, Wozney JM, et al. rhBMP-2 significantly enhances guided bone regeneration. *Clin Oral Implants Res*. 2004 Apr; 15(2):194-204.
- 27-Jung RE, Glauser R, Scharer P, Hammerle CHF, Sailer HF, Weber FE. Effect of rhBMP-2 on guided bone regeneration in humans. *Clin Oral Implants Res*. 2003 Oct; 14(5):556-68.
- 28-Cochran DL, Jones AA, Lilly LC, Fiorellini JP, Howell H. Evaluation of recombinant human bone morphogenetic protein-2 in oral application

- iclude use of endosseous implants: 3-year results of a pilot study in humans. *J Periodontol*. 2000 Aug; 71(8):1241-57.
- 29-Takahashi Y, Yamamoto M, Yamada K, Kawakami O, Tabata Y. Skull bone regeneration in nonhuman primates by controlled release of bone morphogenetic protein-2 from a biodegradable hydrogel. *Tissue Eng*. 2007 Feb;13(2): 293-300.
- 30-Yamamoto M, Takahashi Y, Tabata Y. Enhanced bone regeneration at a segmental bone defect by controlled release of bone morphogenetic protein-2 from a biodegradable hydrogel. *Tissue Eng*. 2006 May; 12(5):1305-11.
- 31-Arosarena O, Collins W. Comparison of BMP-2 and -4 for rat mandibular bone regeneration at various doses. *OrthodCraniofac Res*. 2005 Nov; 8(4):267-76.
- 32-Kim J, Kim IS, Cho TH, Lee KB, Hwang SJ, Tae G, et al. Bone regeneration using hyaluronic acid-based hydrogel with bone morphogenic protein-2 and human mesenchymal stem cells. *Biomaterials*. 2007 Apr; 28(10):1830-7.
- 33-Chu TG, Warden SH, Turner CH, Stewart RL. Segmental bone regeneration using a load-bearing biodegradable carrier of bone morphogenetic protein-2. *Biomaterials* 2007 Jan; 28(3): 459-67.
- 34-Allegrini S, Yoshimoto M, Salles MB, König B. Bone regeneration in rabbit sinus lifting associated with bovine BMP. *J Biomed Mater Res B Appl Biomater*. 2004 Feb 15; 68(2):127-31.
- 35-Kleinheinz J, Stratmann U, Joos U, Wiesmann HP. VEGF-Activated Angiogenesis during Bone Regeneration. *J Oral Maxillofac Surg*. 2005 Sep; 63(9):1310-6.
- 36-Samee M, Kasugai S, Kondo H, Ohya K, Shimokawa H, Kuroda S. Bone morphogenetic protein-2 (BMP-2) and vascular endothelial growth factor (VEGF) transfection to human periosteal cells enhances osteoblast differentiation and bone formation. *J Pharmacol Sci*. 2008 Sep; 108(1):18-31.
- 37-Hokugo A, Sawada Y, Hokugo R, Iwamura H, Kobuchi M, Kambara T, et al. Controlled release of platelet growth factors enhances bone regeneration at rabbit calvaria. *Oral Surg Oral Med Oral Pathol Oral RadiolEndod*. 2007 Jul; 104(1):44-48.
- 38-Fuerst G, Gruber R, Tangl S, Mittlböck M, Sanroman F, Watzek G, et al. Effect of platelet-released growth factors and collagen type I on osseous regeneration of mandibular defects. *J Clin Periodontol*. 2004 Sep; 31(9):784-790.
- 39-Ehrhart NP, Hong L, Morgan AL, Eurell JA, Jamison RD. Effect of transforming growth factor- β 1 on bone regeneration in critical-sized bone defects after irradiation of host tissues. *Am J Vet Res*. 2005 Jun;66(6):1039-1045.
- 40-Marzouk KM, Gamal AY, Al-Awady AA, Sharawy MM. Platelet-derived growth factor BB treated osteoprogenitors inhibit bone regeneration. *J Oral Implantol*. 2008; 34(5):242-247.
- 41-Sawada Y, Hokugo A, Nishiura A, Hokugo R, Matsumoto N, Morita S, et al. A trial of alveolar cleft bone regeneration by controlled release of bone morphogenetic protein: an experimental study in rabbits. *Oral Surg Oral Med Oral Pathol Oral RadiolEndod*. 2009 Dec; 108(6):812-820.
- 42-Patel ZS, Young S, Tabata Y, Jansen JA, Wong ME, Mikos AG, et al. Dual delivery of an angiogenic and an osteogenic growth factor for bone regeneration in a critical size defect model. *J Bone*. 2008 Nov; 43(5):931-940.
- 43-Canter HI, Vargel I, Korkusuz P, Oner F, Gungorduk DB, Cil B, et al. Effect of use of slow release of bone morphogenetic protein-2 and transforming growth factor-beta-2 in a chitosan gel matrix on cranial bone graft survival in experimental cranial critical size defect model. *Ann Plast Surg*. 2010 Mar;64(3):342-350.
- 44-Chung Y, Ahn KM, Jeon SH, Lee SY, Lee JH, Tae G. Enhanced bone regeneration with BMP-2 loaded functional nanoparticle-hydrogel complex. *J Control Release*. 2007 Aug; 121(1-2): 91-99.
- 45-Kaitoa T, Myouia A, Takaoka K, Saito N, Nishikawa M, Tamai N, et al. Potentiation of the activity of bone morphogenetic protein-2 in bone

- regeneration by a PLA-PEG/hydroxyapatite composite. *J Biomaterials*. 2005 Jan; 26(1):73-79.
- 46-Asamura S, Mochizuki Y, Yamamoto M, Tabata Y, Isogai N. Bone regeneration using a bone morphogenetic protein-2 saturated slow-release gelatin hydrogel sheet, evaluation in a canine orbital floor fracture model. *Ann Plast Surg*. 2010 Apr; 64(4):496-502.
- 47-Smeets R, Maciejewski O, Gerressen M, Spiekermann H, Hanisch O, Riediger D, et al. Impact of rhBMP-2 on regeneration of buccal alveolar defects during the osseointegration of transgingival inserted implants. *Oral Surg Oral Med Oral Pathol Oral Radiol Endod*. 2009 Oct; 108(4):e3-e12.
- 48-Tatakis DN, Koh A, Jin L, Wozney JM, Rohrer MD, Wikesjö UM. Peri-implant bone regeneration using recombinant human bone morphogenetic protein-2 in a canine model: a dose-response study. *J Periodont Res*. 2002 Apr; 37(2):93-100.
- 49-Sykaras N, Triplett RG, Nunn ME, Iacopino AM, Opperman LA. Effect of recombinant human bone morphogenetic protein-2 on bone regeneration and osseointegration of dental implants. *Clin Oral Implants Res*. 2001 Aug; 12(4):339-349.
- 50-Jung RE, Windisch SI, Eggenschwiler AM, Thoma DS, Weber FE, Hämmerle CHF. A randomized-controlled clinical trial evaluating clinical and radiological outcomes after 3 and 5 years of dental implants placed in bone regenerated by means of GBR techniques with or without the addition of BMP-2. *Clin Oral Implants Res*. 2009 Jul; 20(7):660-666.
- 51-Chen B, Lin H, Wang J, Zhao Y, Wang B, Zhao W, et al. Homogeneous osteogenesis and bone regeneration by demineralized bone matrix loading with collagen-targeting bone morphogenetic protein-2. *Biomaterials* 2007 Feb; 28(6):1027-1035.
- 52-Schwarz F, Ferrari D, Podolsky L, Mihatovic I, Becker J. Initial pattern of angiogenesis and bone formation following lateral ridge augmentation using rhPDGF and guided bone regeneration: an immunohistochemical study in dogs. *Clin Oral Implants Res*. 2010 Jan; 21(1):90-99.
- 53-Nevins M, Camelo M, Nevins ML, Schenk RK, Lynch SE. Periodontal regeneration in humans using recombinant human platelet derived growth factor-BB (rhPDGF-BB) and allogenic bone. *J Periodontol*. 2003 Sep; 74(9):1282-1292.
- 54-Schwarz F, Sager M, Ferrari D, Mihatovic I, Becker JR. Influence of recombinant human platelet-derived growth factor on lateral ridge augmentation using biphasic calcium phosphate and guided bone regeneration: A histomorphometric study in dogs. *J Periodontol*. 2009 Aug; 80(8):1315-1323.
- 55-Yonamine Y, Matsuyama T, Sonomura T, Takeuchi H, Furuichi Y, Uemura M, et al. Effective application of vascular endothelial growth factor to critical sized rat calvaria defects. *Oral Surg Oral Med Oral Pathol Oral Radiol Endod*; 2010 Feb; 109(2):225-231.
- 56-Wernike E, Montjovent M, Liu Y, Wismeijer D, Hunziker EB, Siebenrock KA, et al. VEGF incorporated into calcium phosphate ceramics promotes vascularisation and bone formation *INVIVO*. *Eur Cell Mater*. 2010 Feb; 19:30-40.
- 57-Niedhart C, Maus U, Miltner O, Gräber HG, Niethard FU, Siebert CH. The effect of basic fibroblast growth factor on bone regeneration when released from a novel in situ setting tricalcium phosphate cement. *J Biomed Mater Res A*. 2004 Jun 15; 69(4):680-685.
- 58-Akagawa Y, Kubo T, Koretake K, Hayashi K, Doi K, Matsuura A, et al. Initial bone regeneration around fenestrated implants in Beagle dogs using basic fibroblast growth factor-gelatin hydrogel complex with varying biodegradation rates. *J Prosthodont Res*. 2009 Jan; 53(1):41-47.
- 59-Yuan Q, Kubo T, Doi K, Morita K, Takeshita R, Katoh S, et al. Effect of combined application of bFGF and inorganic polyphosphate on bioactivities of osteoblasts and initial bone regeneration. *Acta Biomater*. 2009 Jun; 5(5):1716-1724.
- 60-Murakami S, Takayama S, Kitamura M, Shimabukuro Y, Yanagi K, Ikezawa K, et al.

- Recombinant human basic fibroblast growth factor (bFGF) stimulates periodontal regeneration in class II furcation defects created in beagle dogs. *J Periodontal Res.* 2003 Feb; 38(1):97-103.
- 61-Ichinohe N, Kuboki Y, Tabata K. Bone regeneration using titanium nonwoven fabrics combined with fgf-2 release from gelatin hydrogel microspheres in rabbit skull defects. *Tissue Eng Part A.* 2008 Oct; 14(10):1663-1671.
- 62-Kitamura M, Nakashima K, Kowashi Y, Fujii T, Shimauchi H, Sasano T, et al. Periodontal tissue regeneration using fibroblast growth factor -2: randomized controlled phase II clinical trial. *PLoS One.* 2008 Jul 2; 3(7):e2611.
- 63-Ripamonti U, Parak R, Petit J-C. Induction of cementogenesis and periodontal ligament regeneration by recombinant human transforming growth factor- β 3 in Matrigel with rectus abdominis responding cells. *J Periodontal Res.* 2009 Feb; 44(1):81-87.
- 64-Gruber RM, Ludwig A, Merten HA, Achilles M, Poehling S, Schliephake H. Sinus floor augmentation with recombinant human growth and differentiation factor-5 (rhGDF-5): A histological and histomorphometric study in the Goettingen miniature pig. *Clin Oral Implants Res.* 2008 May; 19(5):522-529
- 65-Weng D, Poehling S, Pippig S, Bell M, Richter EJ, Zuhr O, et al. The effects of recombinant human growth/ differentiation factor-5 (rhGDF-5) on bone regeneration around titanium dental implants in barrier membrane-protected defects: A pilot study in the mandible of beagle dogs. *Int J Oral Maxillofac Implants.* 2009 Jan-Feb; 24(1):31-37.
- 66-Kim T-G, Wikesjo UME, Cho K-S, Chai JK, Pippig SD, Siedler M, et al. Periodontal wound healing/ regeneration following implantation of recombinant human growth/ differentiation factor-5 (rhGDF-5) in an absorbable collagen sponge carrier into one-wall intrabony defects in dogs: a dose-range study. *J Clin Periodontol.* 2009 Jul; 36(7):589-597.
- 67-Schwarz F, Ferrari D, Sager M, Herten M, Hartig B, Becker J. Guided bone regeneration using rhGDF-5- and rhBMP-2 coated natural bone mineral in rat calvarial defects. *Clin Oral Implants Res.* 2009 Nov; 20(11):1219-1230.
- 68-Kikuchi T, Kubota S, Asaumi K, Kawaki H, Nishida T, Kawata K, et al. Promotion of bone regeneration by CCN2 incorporated into gelatin hydrogel. *Tissue Eng Part A.* 2008 Jun; 14(6): 1089-1098.
- 69-Christgau M, Moder D, Hiller KA, Dada A, Schmitz G, Schmalz G. Growth factors and cytokines in autologous platelet concentrate and their correlation to periodontal regeneration outcomes. *J Clin Periodontol.* 2006 Nov; 33(11): 837-845.