

Clinical Accuracy of Ipex Apex Locator for Measurement of Root Canal Length of Primary Molars

M. Karami Nogorani¹, M. Zare Jahromi², ✉ Z. Dehghan³, R. Talaei⁴.

¹Associate Professor, Department of Pediatric Dentistry, School of Dentistry, Islamic Azad University of Khorasgan Branch. Isfahan, Iran

²Assistant Professor, Department of Endodontics, School of Dentistry, Islamic Azad University of Khorasgan Branch. Isfahan, Iran

³Postgraduate Student, Department of Pediatric Dentistry, School of Dentistry, Islamic Azad University of Khorasgan Branch.

Isfahan, Iran

⁴Dentist

Abstract

Background and Aim: Radiography is the most commonly used technique for root canal length determination; but its application in pedodontics is difficult due to problems namely the radiation hazards, superimposition of permanent teeth buds and uncooperative children. Electronic apex locator (EAL) is used for determination of root canal length. The aim of this study was to assess the accuracy of an Electronic Apex Locator (Ipex) in measuring the root canal length of primary teeth in-vivo.

Materials and Methods: This clinical study was conducted on 50 root canals of primary teeth that had to be extracted. After local anesthesia induction and caries removal, access cavities were prepared and the length of root canals was measured using Ipex Electronic Apex Locator. After the extraction of teeth, the actual length of canals was measured using a #15 K file from a reference point. Data were analyzed using paired t-test and intra-class correlation coefficient.

Results: The accuracy of Ipex was 20% for accurate determination of actual root canal length, 66% for estimation within ± 0.5 mm of the apex and 80% for estimation within ± 1 mm of the apex. Paired t-test revealed a significant difference between the actual root canal length and the length displayed by Ipex ($p < 0.001$). A direct strong correlation existed between the length measured by Ipex and the actual root canal length ($r = 0.957$).

Conclusion: Ipex had a tendency to underestimate the actual root canal length. Since the working length is shorter than the actual root canal length, Ipex may be used for endodontic treatment of primary teeth.

Key Words: Electronic apex locator, Ipex, Endodontic treatment, Canal length, Primary teeth

✉ Corresponding author:
M. Zare Jahromi, Assistant
Professor, Department of
Endodontics, School of Dentistry,
Islamic Azad University of
Khorasgan Branch. Isfahan, Iran
hiva1378maryam@yahoo.com

Received: 23 Feb 2013

Accepted: 4 July 2013

Journal of Islamic Dental Association of IRAN (JIDAI) Winter 2014 ;2, (1)

Introduction

Preservation of primary teeth is important because their loss will cause malocclusion, impaired mastication and future orthodontic problems [1]. Endodontic treatment of permanent teeth has specific principles. But, in primary teeth, the root apex changes due to resorption and deposition of hard tissue. Anatomy of the root canals of primary teeth cannot be precisely determined. As the resorption

advances, apical foramen loses its relation to the anatomic apex and is coronally repositioned. Thus, radiographic confirmation of canal length may be erroneous [2-4]. Resorption may extend into the root canals and more connections other than through the apical foramen or accessory canals may be established between the root canal system and periapical tissue. This occurs in all root surfaces [2]. The effects of endodontic treatment of pri-

primary teeth on development of permanent teeth buds are among the concerns of clinicians. Inappropriate manipulation of primary tooth apex may compromise and damage the permanent tooth buds [5]. In order to prevent the passage of material or instruments through the apex, the working length has to be considered 2-3 mm shorter than the radiographic apex [2]. For measurement of canal length, long-cone parallel technique and electronic apex locator can be used to ensure maximum precision.

Radiography is commonly used for working length determination. However, this method is associated with some problems in children due to their poor cooperation and small mouth. Use of apex locator has made root canal therapy of permanent teeth easier [6]. Considering the problems associated with working length determination in primary teeth and introduction of new versions of electronic apex locators into the market, we sought to assess the accuracy of an electronic apex locator for working length determination of primary teeth.

Electronic apex locator for determination of root canal length was invented by Coster. This invention was re-evaluated by Suzuki in 1942 [7].

Katz et al, in 1996 evaluated the efficacy of Root ZX electronic apex locator for measurement of root canal length in primary teeth with partial resorption in an alginate model imitating in vivo conditions. Measurements made by Root ZX and on radiograph were compared in both wet and dry canal environments. They concluded that Root ZX is a preferred adjunct for measurement of root canal length in primary teeth [8]. In 2003, Kielbassa et al. evaluated the accuracy of Root ZX for measurement of root canal length in primary teeth. The Pearson's correlation test confirmed its adequate accuracy with a tendency to underestimate the canal length. They stated that Root ZX can be successfully used for primary teeth working length determination especially in uncooperative children [4]. Heidari and Yekta in an experimental study in 2007 evaluated the accuracy of Dentaport ZX electronic apex locator for working length determination in resorbed primary teeth and recommended its use particularly for uncooperative children [9].

In 2008, Ghaemmaghami et al, clinically assessed the accuracy of Root ZX for determination of root canal length of primary incisors and concluded that

it can be definitely used for this purpose [10]. In 2009, Leonardo et al, measured the canal length of primary teeth at different stages of resorption ex-vivo using digital signal processing system and reported its high efficacy [11]. Beltram et al, in 2011 investigated the accuracy of Root ZX for use in primary teeth ex-vivo and in-vivo and concluded that it is very well capable of measuring the working length of primary teeth regardless of the presence or absence of root resorption with ± 1 mm precision in over 90% of cases [12]. Odabas et al, in 2011 concluded that electronic apex locator was beneficial for root canal length determination in primary teeth with and without root resorption [13]. Considering the increasing use of apex locators and problematic measurement of root canal length of primary teeth, this study aimed to determine the accuracy of an electronic apex locator for root canal length measurement in primary teeth.

Materials and Methods

This was a clinical experimental study. The study design was approved by the Ethics Committee of Khorasgan Azad University. Patients were selected among children presenting to this university seeking dental treatment. After establishing the need for primary molar tooth extraction due to orthodontic or clinical purposes and radiographic confirmation of diagnosis, the teeth were selected. Teeth with resorption less than 1/3 of the root length were selected since primary tooth RCT is only recommended when at least 2/3 of the root length is present [9]. Written informed consent was obtained from parents. The required sample size was 50 root canals. Anesthesia was induced, the tooth was isolated, caries were removed using #330 carbide round bur (Brasseler, Savannah, GA, USA) for high-speed and #6 carbide round bur (Brasseler, Savannah, GA, USA) for low speed handpiece. Pulp chamber roof was removed, canal orifices were found and access cavity was prepared. If the pulp was vital, pulpotomy was done by excavation of pulp tissue from the pulp chamber using an excavator and #6 round carbide bur for low-speed hand piece. Pulp chamber was rinsed with saline solution and dried with sterile cotton pellet. The area was isolated by cotton rolls. In case of vital pulp, pulp tissue of the canals was removed as much as possible (based on patient

cooperation) using #15 and #20 K files (Mani Inc., Tochigi, Japan) in order to match the patients in terms of absence of vital pulp tissue and minimizing the confounding factors. Ipex electronic apex locator (NSK, Japan) was then used. Its lip clip was attached to the lip commissure contralateral to the respective tooth. This specific device (Ipex) was selected since it is highly popular in Iran and not many studies have evaluated its efficacy. Number 15 K file (Mani Inc., Tochigi, Japan) was introduced into the canal and the file clip was attached. The display monitor of Ipex shows the path of file into the canal towards the apex. The root length is displayed in sections on the monitor to 2mm to the apical foramen or where the canal and periapical tissue meet. Each section indicates 0.1 mm. In our study, working length was calculated to 0.5 mm (5 sections) to the actual length. A stable point on the occlusal surface was selected as the reference point and marked with nail varnish separately for each canal. After measuring the lengths of all available canals, the tooth was extracted by forceps. Attention was paid not to fracture the crown or roots.

After tooth extraction, the actual length of canals was measured using a #15 K file and the marked reference point. File was introduced into the canal until the tip was visible at the apex. The file was extracted and the distance from the tip to the stop was measured by a gauge and recorded as the actual canal length. Working length was also calculated by subtracting 1 mm from the actual canal length from the most-distant beveled point. For each primary root canal, 3 values were recorded: working length, actual canal length and length measured by Ipex. A total of 150 obtained values were statistically analyzed using paired t-test,

Pearson's correlation test and linear regression analysis.

Results

Canal length of 50 primary teeth was clinically measured using Ipex apex locator. Their actual length and working length were also measured after their extraction. The obtained data are summarized in Table 1. This study showed that the accuracy of Ipex for measurement of actual canal length was 20%. This rate was 66% for estimation in the range of ± 0.5 mm of the apical foramen and 80% for estimation in the range of ± 1 mm of the apical foramen. Pearson's correlation test showed a strong direct linear correlation between the measured canal length by Ipex and the actual canal length (Diagram 1). The regression line indicated the actual canal length in relation to the value obtained by Ipex (Diagram 1).

The mean actual canal length was 11.65 ± 2.48 mm and the value measured by Ipex was 11.07 ± 2.35 mm. Paired t-test showed that this difference was statistically significant ($r=0.957$, $p=0.001$).

The working length in this study was considered 1 mm shorter than the actual root canal length. The mean working length was approximately 0.42 mm shorter than the mean length measured by Ipex. The actual canal length was 0.58 ± 0.7202 mm longer than the length measured by Ipex (Table 1). The accuracy of Ipex for exact determination of canal length was 20% and this device tended to underestimate the canal length (its accuracy was 88% for length estimation within 2 mm of the apical foramen; in 68% of cases, the estimated length was shorter, in 20% was equal and in 12% was longer than the actual canal length) (Table 2).

Table 1. Comparison of canal length measured by different methods

--	Total	Minimum	Maximum	Mean	Standard deviation
Canal length measured by Ipex in mm	50	6/50	16	11/066	2/3511
Actual canal length after extraction in mm	50	6/50	16	11/646	2/4762
Working length (in mm)*	50	5/50	15	10/646	2/4762
RL ₁ -AL ₂	50	-0/5	2	0/58	0/7202
Valid N (list wise)	50				

*Working length=Actual length-1mm

RL₁= Actual canal length

AL₂= Canal length measured by apex

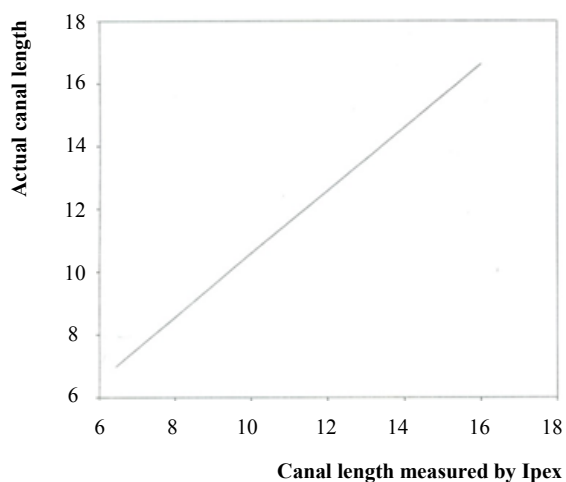


Diagram 1. The regression line of actual canal length relative to the value measured by Ipex

Table 2. Frequency distribution of the canal length values obtained by Ipex compared to the actual canal length

Obtained value	Number	Percentage
Over-estimation	6	12
Equal	10	20
Underestimation	34	68
Total	50	100

Discussion

Root canal length determination is an important step in endodontic treatment of primary and permanent teeth. The end point of root canal therapy should be very well specified to prevent irritation of the periapical tissue and damage to the permanent tooth bud in primary teeth [5].

Before the invention of apex locators, determination of root canal length was mainly based on radiographic interpretation. Estimation of the anatomy of primary molar teeth is difficult due to resorption and hard tissue deposition. In order to achieve aseptic conditions, root canal cleaning and shaping should be extended by up to 2/3 of the canal length [2]. Radiography is the most common method of root canal length measurement. However, it is not considered an ideal technique due to its limitations. Since the introduction of electronic apex locators, the accuracy of these systems has been the subject of numerous investigations. However, most of these studies have been conducted on permanent teeth [13]. Some in vitro studies have also evaluated their accuracy for root canal length measurement in primary teeth.

Apical constriction was not present in many of the teeth evaluated in our study. Thus, after extraction, a file was introduced into the canal until the tip was visible at the apex and then the working length was determined by subtracting 1mm from the actual length. Heidari and Yekta in their in vitro study evaluated the resorbed primary roots and reported accuracy higher than our obtained value. The reason may be the different in-vitro conditions [9]. Our results were similar to those of Katz et al. However, higher accuracy in their study may be due to the in-vitro design of their study, type of apex locator (Root ZX) and small number of samples [8]. Under in-vitro conditions, the gel that simulates periradicular tissues cannot penetrate into the canal space similar to the condition in resorbed and non-resorbed roots. Thus, the apex locator cannot differentiate between these two conditions (resorbed or non-resorbed roots) under in-vitro conditions (14, 15). Our study found a lower accuracy for determination of the actual canal length by the Ipex compared to the study by Ghaemmaghami et al, and Ipex in our study had a tendency to underestimate the canal length compared to Root ZX in their study [10].

In a study by Leonard in 2009, a high correlation existed between the actual length and the value measured by apex locator. The reason could be the fact that the actual length was considered 1mm shorter than the apical foramen or apical resorption bevel. In the majority of teeth evaluated in their study some degrees of root resorption existed but no comparison was made between the resorbed and non-resorbed teeth in this respect [11]. In the study by Beltrame et al, no difference was found in length measurement between resorbed and non-resorbed teeth with Root ZX and it had 90% accuracy in length determination within ± 1 mm of the actual length [12]. Angwaravong et al, in 2009 found that despite the presence of root resorption in primary teeth, apex locator is capable of optimal canal length determination [16].

In our study, the difference between the visual measurement and the value displayed by the Ipex (deviation from the actual canal length) was -0.58 ± 0.7202 (Table 1). This finding indicates that Ipex tends to underestimate the canal length. This

finding confirms the results of Kielbassa et al and Katz et al [4, 8]. Underestimation of length by apex locator may be explained by the fact that the device alarms when the file tip contacts the periapical tissue. In many cases, the periapical tissue penetrates into the canal to some extent. This penetration is greater in open apex teeth and those with a wide apex and thus file tip contacts the tissue penetrated into the canal before reaching the apical foramen resulting in underestimation of the length [14]. Since in the pulpectomy of primary teeth, working length is considered shorter than the actual canal length, this underestimation may be favorably acceptable.

Conclusion

Considering the study results and in order to avoid the drawbacks of radiography (radiation exposure of the children), Ipex apex locator may be used for working length determination in primary teeth particularly in uncooperative children to facilitate the treatment procedure and decrease the pulpectomy procedure time.

References

- 1- Mc Donald RE, Avery DR. Dentistry for the child and adolescent. 9thed. St. louis: Mosby; 2011,522.
- 2- Hargreaves KM, Cohen S, Cohen's Pathways of the Pulp. 10th ed. St. louis: Mosby; 2010,654-680.
- 3- Shahrabi M, Seraj B, Heidari. Accuracy evaluation of a special electronic apex locator in measuring primary teeth root length in clinical conditions. J Dent, Tehran University of Medical Sciences. 2006 Jan;(1):79-83. [Persian].
- 4- Kielbassa AM, Muller U, Munz I, Monting JS. Clinical evaluation of measuring accuracy of root ZX in primary teeth. Oral Surg Oral Med Oral Pathol Oral Radio & Endod. 2003 Jan; 95(1):94-100.
- 5- Guideline for pulp therapy for primary and young permanent teeth. American academy of pediatric dentistry. 2006: (cited 2006 march 12). available at. www.hon.Ch/ conduct. html.
- 6- Shahrabi M, Seraj B, Nekoufar MH, Mosharafian SH, Kharazifard MJ. Accuracy evaluation of a special electronic apex locator in measuring primary teeth root length in laboratory conditions. J of Dent, Tehran University of Medical Sciences. 2004 Jan;17(1):32-40. (Persian)
- 7- Suzuki K. Experimental study on iontophoresis. Japanese J of Stomatology. 1942;16:411-429.
- 8- Katz A, Mass E, Kaufman Arie Y. Electronic apex locator: A useful tool for root canal treatment in the primary dentition. J Dent Child. 1996 Jun; 63(6):414-417.
- 9- Heidary A, Jalaliyekta H. Accuracy evaluation of an electronic apex locator in measuring resorped primary teeth root canal length in laboratory conditions J of Dent, Mashhad University of Medical Sciences. 2008 Feb;32(2):117-122. (Persian)
- 10- Ghaemmaghami S, Eberle J, Duperon D. Evaluation of the Root ZX apex locator in primary teeth. Pediat Dent. 2008 Jun;30(6):496-498.
- 11- Leonardo MR, Da Silva LA, Nelson-Filo P, Da Silva RA, Lucisano MP. Ex vivo accuracy of an apex locator using digital signal processing in primary teeth. Pediat; 2009 Apr; 31(4):320-2.
- 12- Beltrame AP, Triches TC, Sartori N, Bolan M. Electronic determination of root canal working length in primary molar teeth: An invivo and ex vivo study. Int Endod J. 2011 May; 44(5):402-613.
- 13- Odabaş ME, Bodur H, Tulunoğlu O, Alaçam A. Accuracy of an electronic apex locator: a clinical evaluation in primary molars with and without resorption. J Clin Pediat Dent. 2011 March; 35(3): 255-8.
- 14- Heidari A. Shahrabi M. Seraj B. Accuracy comparison of Dentaport ZX in root canal length measurement in resorped versus unresorped primary teeth. Tabibe Shargh J. 2008 Jan; 10(1):45-51. (Persian)
- 15- Gordon MP, J Chandler NP. Electronic apex locators. Int Endod J. 2004 Jul;37(4):425-437.
- 16- Angwaravong O, Panitvisai P. Accuracy of an electronic apex locator in primary teeth with root resorption. Int Endod J. 2009 Feb; 42(2):115-21.