

## Oral Reconstruction of Hemi-Mandibulectomy Patients by Implant Overdenture: Report of Two Cases

Amir Reza Hendi<sup>1</sup>, Mehran Falahchai<sup>1</sup>, Mahsa Koochaki<sup>2</sup>, Donya Maleki<sup>3</sup>

<sup>1</sup> Assistant Professor, Dental Sciences Research Center, Department of Prosthodontics, School of Dentistry, Guilan University of Medical Sciences, Rasht, Iran

<sup>2</sup> Department of Oral and Maxillofacial Disease, School of Dentistry, Tehran University of Medical Sciences, Tehran, Iran

<sup>3</sup> Student Research Committee, School of Dentistry, Guilan University of Medical Sciences, Rasht, Iran

### Abstract

**Introduction:** Loss of mandibular continuity, jaw deviation, extensive freely movable soft tissues, and difficulty in mastication, swallowing, and speech are the results of hemi-mandibulectomy, which adversely affect the patients' quality of life. Management of such patients by fixed or removable prostheses is a complex and challenging approach as the type of prosthesis is a determinant factor in successful rehabilitation.

**Case Presentation:** The present report describes prosthetic rehabilitation of two patients who underwent hemi-mandibulectomy due to osteosarcoma. After clinical and paraclinical evaluations and multidisciplinary consultations, it was decided to use implant-supported removable overdenture with stud attachments and an open-structure framework for them.

**Results:** Jaw reconstruction and dental rehabilitation of hemi-mandibulectomy patients are complicated procedures. However, with regard to developments in dental science, the clinicians have different options to fulfill the esthetic and functional demands of such patients. The current paper showed that implant-supported removable prostheses with stud attachments can successfully rehabilitate the hemi-mandibulectomy defects when the interocclusal space is limited and achieving the implants' parallelism is a challenge due to the nature of hemi-mandibulectomy procedure.

**Key Words:** Mandibular Osteotomy; Maxillofacial Prosthesis; Odontogenic Tumors; Rehabilitation

✉ Corresponding author:  
Donya Maleki, Student  
Research Committee, School of  
Dentistry, Guilan University of  
Medical Sciences, Rasht, Iran

donyamaleki93@gmail.com

Received: 16 June 2020

Accepted: 26 Nov 2020

➤ **Cite this article as:** Hendi AR, Falahchai M, Koochaki M, Maleki D. Oral Reconstruction of Hemi-Mandibulectomy Patients by Implant Overdenture: Report of Two Cases. J Iran Dent Assoc. 2021; 33 (3-4):84-92. doi: 10.52547/jida.33.3.4.84

### Introduction

Odontogenic tumors have an aggressive nature and have a high incidence in the posterior mandible, which can result in mandibular destruction (1,2). According to the lesion's extension, the treatment plan involves hemi-mandibulectomy with or without

radiotherapy or chemotherapy (3,4). After tumor removal, rehabilitation of structures in terms of function, and esthetics, and improvement of quality of life are among the main goals of clinicians (4,5). To reconstruct the jaw, two steps have been recommended namely jaw reconstruction and dental rehabilitation.

Nowadays, the free fibula flap has gained interest in jaw reconstruction as this bone has adequate volume to shape the resected part of the mandible (3). It is notable to mention that the skin paddle or the lining mucosa is the only soft tissue we achieve after surgery (and not the attached gingiva or the fixed mucosa), making the dental reconstruction even more challenging (6,7). Without paying attention to the type of free bone flap used, the shallow vestibules are also a serious complaint (8), which can be due to inequality of fibula-native bone complex and uneven soft tissue thickness (6).

The treatment options for dental reconstruction include conventional removable prostheses, implant-supported fixed prostheses, and implant-supported removable prostheses. In hemi-mandibulectomy, conventional prostheses may not be appropriate (2,9) because they are incompatible with excessive soft tissue contour and defective bone morphology (2). Also, poor retention of conventional prostheses may lead to mucosal trauma after radiotherapy (10). Implant-supported prostheses are a welcomed solution for these patients, as they provide good retention, stability, and support (3,10). In addition, patients can chew various foods easier and can speak more comfortably with implant-supported prostheses (11). There are randomized and non-randomized clinical trials showing the superiority of implant-supported prostheses compared with conventional prostheses (11-13).

Some of the most important functional issues that affect the health-related quality of life include speech, swallowing, and dental rehabilitation. Based on the advantages and disadvantages of conventional prostheses and implant-supported prostheses mentioned above, it has been clarified that implant-supported prostheses can better improve the health-related quality of life (1,12). Although implant-supported fixed prostheses have a long-term success for treatment of edentulous patients, placement of sufficient number of implants for this treatment plan may not be possible due to severe bone resorption and financial limitations (13,14).

Regarding the thin fibula, placement of implants should be carefully considered (15) especially when a thick soft tissue appears at the site due to poor oral hygiene, infection of peri-implant tissue, or implant loss (6,8). This is where implant-supported removable prostheses show better outcomes since they are highly cleanable (4,16). An implant-supported removable denture can splint the implants to distribute the stress on all implants and if one of the implants fails, the prosthesis is still useable (3,15). Considering all the above, it could be concluded that implant-supported removable prostheses are of great benefits in hemi-mandibulectomy cases (14-16).

A determinant factor in designing implant-supported removable prostheses is the decision about the type of attachment. This is an important decision because the type of attachment has a significant impact on both retention and stability of dentures. The plaque accumulation and peri-implant bleeding are also associated with the type of attachment (11). Previous studies showed that despite good clinical results of bar attachments, they can cause prosthetic complications. The bar attachment commonly requires reactivation of clip (11,17). Nowadays, stud attachments are gaining interest as they can compensate for the un-parallelism of implants, especially in hemi-mandibulectomy cases when an uneven ridge makes the insertion of parallel implants challenging (18).

Herein, we describe step-by-step prosthodontic rehabilitation of two patients with resected mandible after obtaining their written informed consent.

### Case 1

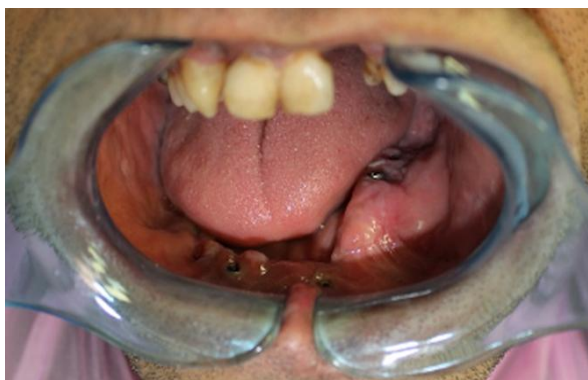A 40-year-old male patient was referred to the Prosthodontics Department of Dentistry Faculty of Guilan University of Medical Sciences. His chief complaint was impaired mastication due to tooth and bone loss requiring prosthetic rehabilitation.

The patient had a history of osteosarcoma cancer involving the right side of the mandible. The lesion was removed by hemi-mandibulectomy. He had edentulism in

the left side from previous extractions. Thus, after hemi-mandibulectomy of the right side, the

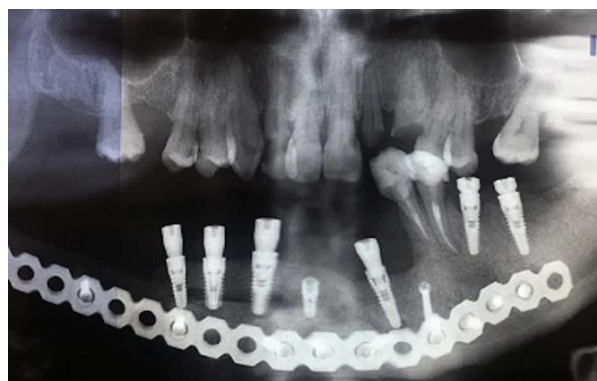patient became completely edentulous in the mandible. After the interview, it was found that radiation therapy had successfully prevented recurrence of the lesion. Also, the resected area had been rehabilitated with a free fibula graft.

In extraoral examination, there was no facial asymmetry and no signs or symptoms of temporomandibular joint disorder. In intraoral examination, there were no residual lesions but the depth of the labial and the lingual vestibule was not enough in the affected side. A notable difference existed between the level of the residual and the resected ridge. Also, the best location for implant placement was chosen to rehabilitate function and esthetics. Six implants (Implantium, Dentium, Korea) were inserted in the remaining mandibular bone; two implants in the native ridge and four in the resected area (Fig. 1). Radiographic examination revealed no pathological findings (Fig. 2).



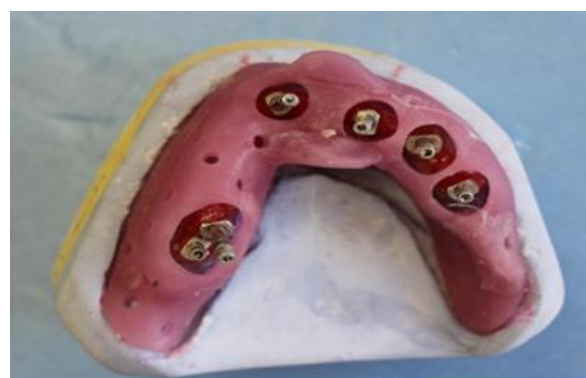**Figure 1.** Intraoral view of the mouth: The implant abutments on the native ridge and the resected area of the mandible can be seen

The healing abutments were unscrewed, and the impression copings were placed. The preliminary one-step impression technique was done with light/putty addition silicone (Panasil, Kettenbach, Hesse, Germany) and a stock open tray. The analog fixtures were screwed to the impression copings, and the impressions were poured with type 4 dental stone (GC Fuji Rock;



**Figure 2.** Panoramic view

GC Corporation, Tokyo, Japan) to obtain the diagnostic casts. The open custom tray was fabricated with visible light-cure resin (Light curing hybrid composite; Plaque Photo, Willmann & Pein GmbH, Barmstedt, Germany) (Fig. 3).

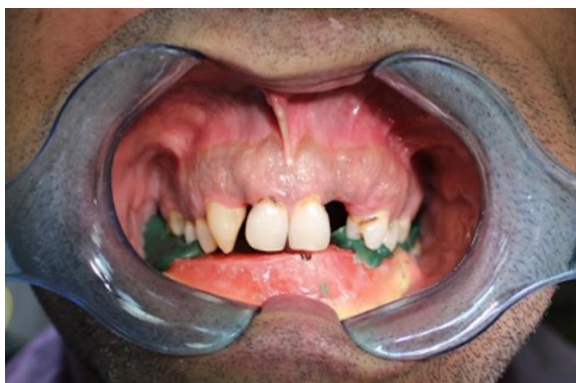

**Figure 3.** Open custom tray

Border molding was performed by impression compound. The final one-step one-phase impression was made by regular-body addition silicone and poured with type 4 dental stone.

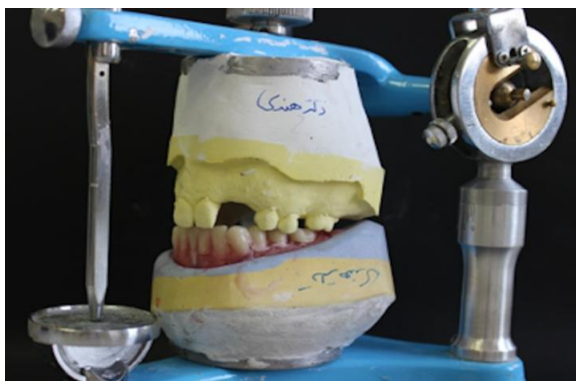
The precision of master cast was checked with a verification jig (GC Corp, Tokyo, Japan). The acrylic record base and occlusal rim were fabricated on the definitive cast and tried in the patient's mouth. The occlusal plane, vertical dimension, and jaw relations were recorded (Fig. 4).

The maxillary cast was mounted with a face bow record, and the mandibular cast was



**Figure 4.** Jaw relation record

mounted against the maxillary arch with a centric record in a non-Arcon semi-adjustable articulator (Mani Articulator, Mani Manufacturing Co., Tehran, Iran). The tooth arrangement was then performed (Ivoclar Vivadent, Schaan, Lichtenstein) (Fig. 5).

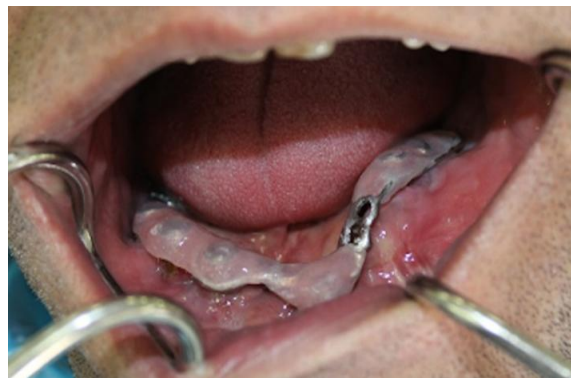

**Figure 5.** Tooth arrangement

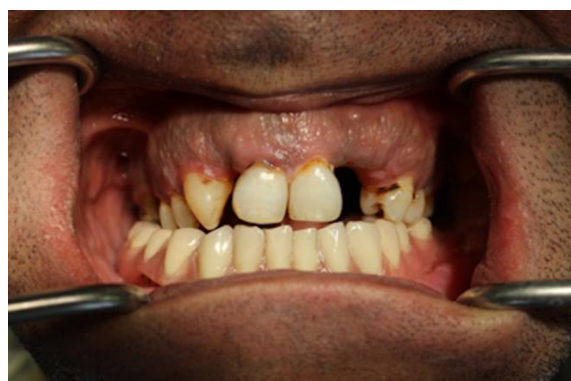The crown-height space was assessed by a putty index made from the tooth arrangement. Regarding the lack of crown-height space, it was decided to use stud attachments (2 x 1 mm; Equator, Implantium, Korea). Next, the chromium-cobalt framework with open structure design was fabricated and tried-in (Fig. 6).

In the next step, the final arrangement of the teeth was done on the framework to establish bilateral balanced occlusion. Heat-polymerizing acrylic resin was used for the definitive prostheses. Finally, the definitive prosthesis was delivered and oral hygiene instructions

were given (Fig. 7). At the 3-year follow-up, the peri-implant soft tissue was healthy, denture retention was good, and the patient was satisfied with the results.



**Figure 6.** Chromium-cobalt framework try-in



**Figure 7.** Definitive prosthesis

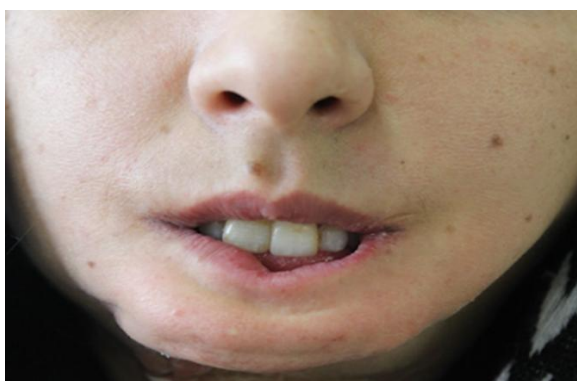## Case 2

A 28-year-old female patient with no systematic problem was referred to the Department of Prosthodontics of Dentistry Faculty of Guilan University of Medical Sciences seeking prosthodontic treatment. She had undergone partial resection of the anterior part of the mandible due to osteosarcoma and suffered from the psychological impact of facing the reality of tooth and jaw loss. Assessment of the medical and dental history of the patient revealed that the resection surgery had been conducted 2 years earlier. Following the surgery, chemotherapy and radiotherapy were

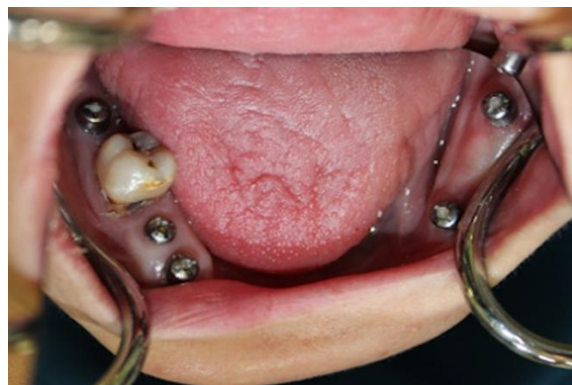

performed to ensure minimizing the risk of tumor recurrence. Then, bone reconstruction surgery was performed using the fibula free flap approach and 5 dental implants were inserted in the remaining bone at the Department of Oral and Maxillofacial Surgery of Dentistry Faculty of Guilan University of Medical Sciences.

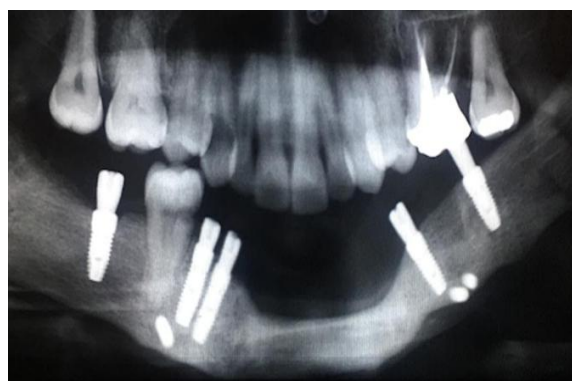
On extraoral examination, the inferior third of the face was smaller than upper and middle thirds. The deviation of the mandible was noticeable towards the reconstructed side on mouth opening. The lip incompetency and microstomia were obvious (Fig. 8).



**Figure 8.** Extraoral view



**Figure 9.** The intraoral view

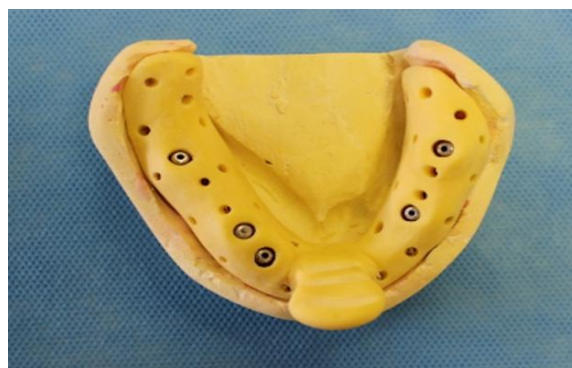

**Figure 10.** Panoramic view

Intraoral assessment showed resection of the anterior mandible with freely movable soft tissues. The only tooth remaining in the mandible was the right first molar which had poor periodontal prognosis due to its deep furcation involvement (Fig. 9). Radiographic examination revealed no pathological findings (Fig. 10).

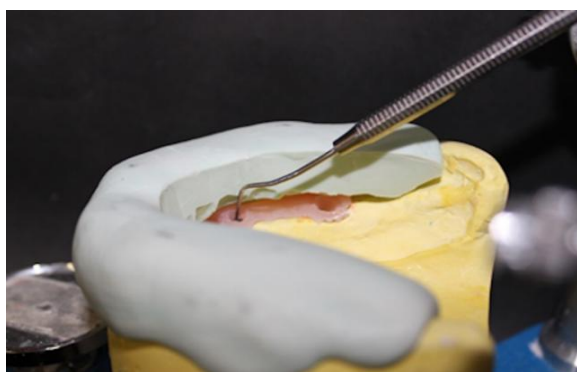
To obtain the primary study casts, following unscrewing of the healing abutments and placing the coping impressions, a preliminary impression was made by light/putty addition silicone (Panasil, Kettenbach, Hesse, Germany) and a stock open tray using one-step technique. The analog fixtures were screwed on the impression copings and the impressions were poured with type 4 dental stone. A customized open tray was made and molded with impression compound. To make the final impression, an open tray

was used with impression copings of the closed tray impression technique. Because of the patient's microstomia, it was not possible to insert the open tray impression copings (Fig. 11).



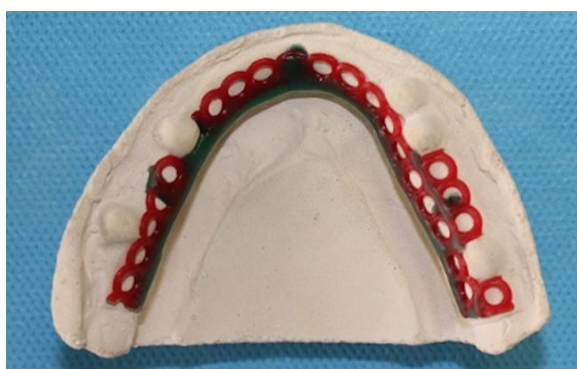**Figure 11.** Customized open tray with closed impression copings

The acrylic denture base and occlusal rim were fabricated on the definitive cast. Then, the casts were mounted in a non-Arcon semi-adjustable articulator according to the recorded jaw relations (Mani Articulator, Mani Manufacturing Co., Tehran, Iran). According to the favorable vertical dimension, the diagnostic tooth arrangement was implemented just like the previous case. The limited crown-height space was confirmed by a putty index made according to the tooth arrangement (Fig. 12). Thus, stud attachments (2 x 1 mm; Equator, Implantium, Korea) were considered.



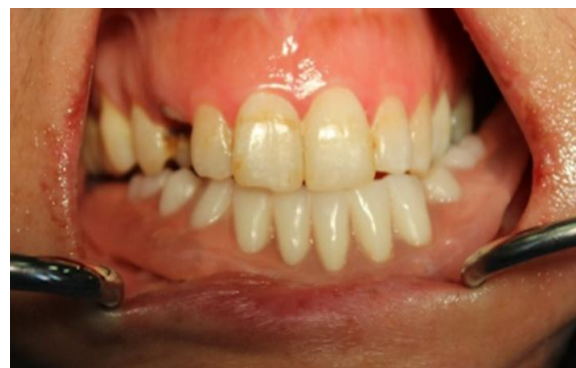**Figure 12.** Checking the CHS

After checking the occlusion, esthetics, and phonetics, the framework was designed with wax pattern (Fig. 13) and cast using chromium-cobalt alloy. In the next appointment, the framework with open structure was tried-in.



**Figure 13.** Wax-up of the framework

Eventually, the laboratory process and arrangement of teeth were completed, providing bilateral balanced articulation. The implant-supported removable overdenture was evaluated and delivered (Fig. 14). Also, oral hygiene instructions were given to the patient, and follow-up appointments were scheduled. The patient was satisfied with the function and esthetics of the prosthesis during the 2-year follow-up.



**Figure 14.** Implant-supported removable overdenture was delivered

## Discussion

Prosthetic rehabilitation supported by dental implants is a well-accepted and predictable treatment option for patients seeking dental reconstruction (7,19). Nonetheless, the type of prosthesis plays an important role in success of treatment (19). Sometimes as a result of hemi-mandibulectomy, the native resected bone or even the native grafted bone may not follow the integrity of the previous ridge and the inter-arch space may be variable in each zone (3). It means that based on the volume of the resected bone, the remaining ridge height is not suitable, and complicates implant placement (3). In this condition, several pieces of literature have suggested performing another augmentation if the first procedure did not provide enough vertical dimension instead of increasing the abutment height (3,20). However, others have discussed that removable prostheses should be considered (4,21). The latter claim was supported by Kumar and Srinivasan (4) who stated implant-supported removable prostheses are of great advantage in

terms of improvement of mastication, psychological impact, and quality of life in long grafts (1,21). Also, a cross-over trial indicated that general satisfaction of patients with removable overdentures was significantly higher than fixed prostheses. This trial provided evidence that when the patients were asked about their speech, they gave a higher score to implant-supported removable prostheses (22). Also, in a review by Al-Harbi, the pooled evidence was conclusive in this regard (17). The speech flaws associated with fixed implant-supported prostheses could be explained by considering the gap between soft tissue and fixed prostheses (14).

The rationale for selection of implant-supported overdentures over fixed dentures is based on the perception that implant-supported overdentures will better create pink interdental papilla than implant-supported fixed prostheses (23). On the other hand, implant-supported removable prostheses have flanges and rehabilitation of unsupported soft tissue is more preferable particularly in the anterior part of the lower jaw (1,21).

According to previous studies, patient's oral hygiene affects the peri-implant tissue health and implant's survival rate (24,25). That is why in patients with poor oral hygiene, implant-supported removable prostheses have been mostly indicated because they are more hygiene-friendly (3,21).

Patients with bone resection without reconstruction/with inappropriate reconstruction are susceptible to mandibular deviation, and the forces applied to the implants are usually cantilevered or angled load (23). Meanwhile, removable prostheses can prevent this deviation and may direct more longitudinal forces (1). However, the implant-supported fixed prostheses cannot be used if the jaw relations are unfavorable or the movements of the resection site are irregular and random (21). Also, if the mouth opening has been reduced or the reconstructed area is extensive, these prostheses are not a suitable treatment plan (21,26,27).

It is worth noting that implant-supported removable prostheses offer significant

advantages in patients with systemic diseases because of the fewer number of implants required compared with implant-supported fixed prostheses (21,25).

If the prognosis of implants is questionable, it is of benefit to use implant-supported removable denture to splint the implants and distribute the stress on all implants so that if one of the implants fails, the prosthesis is still of use whilst implant-supported fixed prosthesis does not have this option (3,15).

The selection of attachment is made by considering the clinical indications, the interocclusal distance, the degree of required retention, inter-implant distance, and orientation of implants (17). The type of attachment has a significant impact on both retention and stability of implant-supported removable dentures (11). Bar attachment can splint the implants for better osseointegration. However, the vertical dimension should be remarkable to insert the bar attachment (17). Hence, in cases with limited crown height space, bar attachments are not appropriate. In addition, repairing, modifying, and remaking a defective bar attachment are difficult (18,28).

Previous literature reproved ball attachments for frequent wear and retention loss after delivery and the necessity of periodic appointments for maintenance, which is undeniable (18,29). In hemi-mandibulectomy cases, achieving the parallelism of implants is complicated and fabrication of prosthesis would be challenging. To facilitate this process, stud attachments, which can compensate for up to 60 degrees of implant angulation are suggested (18). Appropriate stress distribution is the strong point of these attachments (30). The unique design of the stud attachments provides a lower height and smaller diameter; also, they are more affordable compared with other attachments (31). Furthermore, these attachments are hygiene-friendly and have easy aftercare (30,31).

## Conclusion

Ultimately, the options of the implant-supported fixed or removable prostheses are raised for each case but based on

the clinician's opinion, patient's preferences, and ridge conditions, the choice should be made.

## References

1. Marathe AS, Kshirsagar PS. A systematic approach in rehabilitation of hemimandibulectomy: A case report. *J Indian Prosthodont Soc.* 2016 Apr;16(2):208-12.
2. Askin SB, Aksu AE, Calis M, Tulunoğlu İ, Safak T, Tözüm TF. Report of multidisciplinary treatment of an extensive mandibular ameloblastoma with free iliac crest bone flap, dental implants, and acellular dermal matrix graft. *J Oral Implantol.* 2015 Feb;41(1):107-11.
3. Yoon HI. Prosthetic rehabilitation after fibular free flap surgery of mandibular defects in a patient with oral squamous cell carcinoma. *J Craniofac Surg.* 2016 Oct;27(7):e685-8.
4. Kumar VV, Srinivasan M. Masticatory efficiency of implant-supported removable partial dental prostheses in patients with free fibula flap reconstructed mandibles: A split-mouth, observational study. *Clin Oral Implants Res.* 2018 Aug;29(8):855-63.
5. Awadalkreem F, Khalifa N, Ahmad AG, Suliman AM, Osman M. Prosthetic rehabilitation of maxillary and mandibular gunshot defects with fixed basal implant-supported prostheses: A 5-year follow-up case report. *Int J Surg Case Rep.* 2020 Jan 1; 68:27-31.
6. Kumar VV, Ebenezer S, Kämmerer PW, et al. Implants in free fibula flap supporting dental rehabilitation—Implant and peri-implant related outcomes of a randomized clinical trial. *J Craniomaxillofac Surg.* 2016 Nov;44(11):1849-58.
7. Nguyen TT, Eo MY, Myoung H, Kim MJ, Kim SM. Implant-supported fixed and removable prostheses in the fibular mandible. *INT J Implant Dent.* 2020 Dec;6(1):1-9.
8. Kumar VV, Jacob PC, Kekatpure V, Hedne N, Koch FP, Kuriakose MA. The Jugaad technique for jaw reconstruction: denture based inverse planning. *J Maxillofac Oral Surg.* 2016 Sep; 15(3):346-8.
9. Goiato MC, Ribeiro AB, Marinho ML. Surgical and prosthetic rehabilitation of patients with hemimandibular defect. *J Craniofac Surg.* 2009 Nov;20(6):2163-7.
10. Mehra M, Somohano T, Choi M. Mandibular fibular graft reconstruction with CAD/CAM technology: A clinical report and literature review. *J Prosthet Dent.* 2016 Jan;115(1):123-8.
11. Stoumpis C, Kohal RJ. To splint or not to splint oral implants in the implant-supported overdenture therapy? A systematic literature review. *J Oral Rehab.* 2011 Nov;38(11):857-69.
12. Rogers SN, Lowe D, Fisher SE, Brown JS, Vaughan ED. Health-related quality of life and clinical function after primary surgery for oral cancer. *Bri J Oral Maxillofac Surg.* 2002 Feb;40(1):11-8.
13. Goyal P, Manvi S, Arya S. Prosthodontic management of hemimandibulectomy patient: Implants, a better solution. *J Dent Imp.* 2016 Jan;6(1):37-40.
14. Selim K, Ali S, Reda A. Implant supported fixed restorations versus implant supported removable overdentures: a systematic review. *Open Access Maced J Med Sci.* 2016 Dec;4(4): 726-32.
15. Oh SM, Kim JW, Choi SY, et al. Full-Mouth Rehabilitation with Bone-Level Implant Guide and Monolithic Zirconia Prosthesis for Fibular Free Flap Reconstruction: A Case History Report. *Int J Prosthodont.* 2018 Nov;31(6):573-6.
16. Hendi A, Koochaki M. Implant-Supported Removable Partial Denture In A Mandibular Kennedy CL II: A Clinical Report. *J Dentomaxillofac Radiol Pathol Surg.* 2019 Mar; 8(1):56-9.
17. Al-Harbi FA. Mandibular implant-supported overdentures: Prosthetic overview. *Saudi J Med Med Sci.* 2018 Jan;6(1):2-7.
18. Srinivasan M, Kalberer N, Maniewicz S, Müller F. Implant overdentures retained by self-aligning stud-type attachments: A clinical report. *J Pros Dent.* 2020 Jan;123(1):6-14.
19. Maroulakos G, Nagy WW, Ahmed A, Artopoulou II. Prosthetic rehabilitation following lateral resection of the mandible with a long cantilever implant-supported fixed prosthesis: A 3-year clinical report. *J Prosthet Dent.* 2017 Nov;118(5):678-85.



20. Jacobsen HC, Wahnschaff F, Trenkle T, Sieg P, Hakim SG. Oral rehabilitation with dental implants and quality of life following mandibular reconstruction with free fibular flap. *Clin Oral Investig*. 2016 Jan;20(1):187-92.
21. Anne-Gaëlle B, Samuel S, Julie B, Renaud L, Pierre B. Dental implant placement after mandibular reconstruction by microvascular free fibula flap: current knowledge and remaining questions. *Oral oncol*. 2011 Dec; 47 (12):1099-104.
22. Prithviraj, D.R., Madan, V., Harshamayi, P., Kumar, C.G. and Vashisht, R., 2014. A comparison of masticatory efficiency in conventional dentures, implant retained or supported overdentures and implant supported fixed prostheses: a literature review. *J Dent Imp*. 2014 Jul;4(2):153-7.
23. Altintas NY, Kilic S, Altintas SH. Oral Rehabilitation with Implant-Retained Overdenture in a Patient with Down Syndrome. *J Prosthodont*. 2019 Feb;28(2):e617-21.
24. Smolka W. Calvarial grafts for alveolar ridge reconstruction prior to dental implant placement: an update. *Oral Maxillofac Surg*. 2014 Dec;18(4):381-5.
25. Bodard AG, Salino S, Desoutter A, Deneuve S. Assessment of functional improvement with implant-supported prosthetic rehabilitation after mandibular reconstruction with a microvascular free fibula flap: a study of 25 patients. *J Prosthet Dent* 2015 Feb;113(2):140-5.
26. Abdi I, Maleki D. Anterior Mandibular Composite Graft for Regeneration of Knife-Edge Ridges in Implant Surgery: A Treatment Case Report. *Front Dent*. 2020 May;17(10):1-5.
27. Abdi I, Maleki D, Maleki D. A review of advantages and disadvantages of different intraoral and extraoral autogenic osseous grafts in the reconstruction of bony defects. *Journal of Dent Maxillofacial Radiology, Pathology and Surgery*. 2019 Mar 10;8(1):53-5.
28. Kim HY, Lee JY, Shin SW, Bryant SR. Attachment systems for mandibular implant overdentures: a systematic review. *J Adv Prosthodont*. 2012 Nov;4(4):197-203.
29. Kleis WK, Kämmerer PW, Hartmann S, Al-Nawas B, Wagner W. A comparison of three different attachment systems for mandibular two-implant over- dentures: one-year report. *Clin Implant Dent Relat Res*. 2010 Sep;12(3): 209-18.
30. Rutkunas V, Mizutani H, Takahashi H, Iwasaki N. Wear simulation effects on overdenture stud attachments. *Dent Mater J*. 2011 Nov;30(6):845-53.
31. El Mekawy N, Elhawary MY. Clinical evaluation of inter-implant distance influence on the wear characteristics of low-profile stud attachments used in mandibular implant -retained overdentures. *J Clin Exp Dent*. 2019 Jan;11(1): e33-41.