

Prevalence of Mandibular Retromolar Canal on Cone Beam Computed Tomography Scans

K. Amini ¹, R. Ghafari ², SH. Kazemi ³ ✉, F. Bagheri ⁴.

¹ Assistant Professor, Department of Endodontics, School of Dentistry, Islamic Azad University Isfahan (Khorasgan) Branch, Isfahan, Iran

² Postgraduate student, Department of Oral Radiology, School of Dentistry, Islamic Azad University Isfahan (Khorasgan) Branch, Isfahan, Iran

³ Postgraduate student, Department of Endodontics, School of Dentistry, Islamic Azad University Isfahan (Khorasgan) Branch, Isfahan, Iran

⁴ Dentist, Private Office, Qom, Iran

Abstract

Background and Aim: The retromolar canal is an anatomical structure in the mandible and a type of bifid inferior alveolar canal. The retromolar canal may provide accessory innervation to the mandibular molars or contain an aberrant buccal nerve; thus, this canal is of clinical significance. The aim of this study was to evaluate the prevalence of retromolar canal on cone-beam computed tomography (CBCT) scans.

Materials and Methods: In this descriptive-analytical study, 151 inferior alveolar canals in 102 patients (102 unilateral and 49 bilateral) with third molar teeth requiring CBCT scans were evaluated. The scans were evaluated for presence of the retromolar canal and linear measurements (distance to second molar, height and width) were made. The data were analyzed paired t-test and chi square test.

Results: The prevalence of retromolar canal was 7.3% (n=11). With regard to linear measurements, the mean distance from the retromolar canal to the second molar was 12.76 ± 4.3 mm. The mean height of the canal was 6.66 ± 2.18 mm, and the mean width was 1.7 ± 0.6 mm. The presence of retromolar canal was not statistically correlated with sex, side of the jaw or age ($p=0.146$).

Conclusion: The prevalence of retromolar canal on CBCT scans was 7.3%.

Key Words: Cone-Beam Computed Tomography, Mandibular Nerve, Prevalence

✉ Corresponding author:
SH. Kazemi, Postgraduate
student, Department of
Endodontics, School of
Dentistry, Islamic Azad
University Isfahan (Khorasgan)
Branch, Isfahan, Iran

sh.kazemi@khuisf.ac.ir

Received: 16 Jan 2015

Accepted: 12 May 2015

➤ **Cite this article as:** Amini K, Ghafari R, Kazemi SH, Bagheri F. Prevalence of Mandibular Retromolar Canal on Cone Beam Computed Tomography Scans. J Islam Dent Assoc Iran. 2015; 27(3):138-143.

Introduction

Retromolar canal is an anatomical structure in the mandible and a type of bifid inferior alveolar canal. It is branched from the mandibular canal behind the third molar tooth and runs towards the retromolar foramen in the retromolar fossa. Retromolar canal may provide accessory blood supply for the mandibular molars or contain an aberrant buccal nerve. Thus, it is particularly important in mandibular surgeries because inadequate depth of anesthesia may be related to a

type of bifid canal. Also, since this canal contains neurovascular bundles, complications such as traumatic neuroma, paresthesia and bleeding may occur if the canal is traumatized. Moreover, in case of severe mandibular bone resorption the mental foramen may be compressed under mandibular prosthesis and cause discomfort for the patient due to nerve compression [1,2].

The inferior alveolar nerve block is the most important and most commonly administered nerve block in dental treatments. However, it is

associated with high risk of failure even in case of proper injection (approximately 15-20%). Failure of the inferior alveolar nerve block may be due to the high density of alveolar cortical plate, limited access to the inferior alveolar nerve, anatomical variations in this area and presence of accessory innervation adjacent to the mandibular incisors [3]. Also, a theory suggests that accessory innervation is a major cause of failure of inferior alveolar nerve blocks [4,5].

Retromolar foramen is an undetectable anatomical variation of the mandible [6]. The mandibular canal is responsible for the blood supply of the posterior alveolar processes including the mandibular molars and may even contain an aberrant buccal nerve. In case of failure of inferior alveolar nerve block, possible innervation via the retromolar canal should be considered [7].

Von Arx et al, radiographically evaluated the presence of retromolar canal on CBCT scans and panoramic radiographs and reported its prevalence to be 25.6% on CBCT scans and 5.8% on panoramic radiographs [7]. Singh et al. assessed the prevalence of retromolar canal on panoramic radiographs and reported the prevalence of bifid canal to be 4.3%. The prevalence of double canal was reported to be 4%. The highest prevalence of these variations was reported to be at the beginning of the canal path [2].

Dentists must have adequate knowledge and be well aware of the possible anatomical variations during anesthesia administration and implant surgery. Considering the scarcity of available information on presence of retromolar canal or foramen in anatomical textbooks, this study sought to assess the prevalence of retromolar canal and foramen on CBCT scans.

Materials and Methods

This descriptive analytical study was conducted on 102 patients including 50 males and 52 females with a mean age of 34.2 years who had fully erupted mandibular third molar teeth. Although the inferior alveolar canals are located bilaterally in the mandible, a total of 151 inferior alveolar canals adjacent to third molars were evaluated. Patients without third molar teeth, those with a history of mandibular trauma and subjects with distoangular and horizontal third molars were not included.

The prevalence of retromolar canal, the horizontal distance from the canal to the distal surface of second molar tooth, canal height, canal width 3mm below the retromolar foramen and the prevalence of different types according to von Arx et al. were all evaluated [7] (Figure 1).

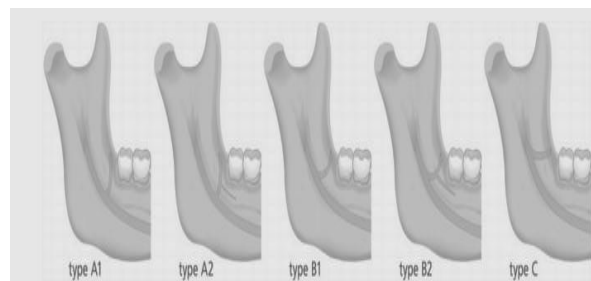


Figure 1. Different types of the retromolar canal

A1: Vertical retromolar canal

A2: Vertical retromolar canal with an additional horizontal branch

B1: Curved retromolar canal

B2: Curved retromolar canal with an additional horizontal branch

C: Horizontal retromolar canal [7]

The CBCT scans were viewed by an oral and maxillofacial radiologist and the horizontal distance from the mesial of retromolar foramen to the cemento-enamel junction at the distal surface of the second molar, the vertical distance from the retromolar canal to the superior border of the inferior alveolar canal and width of the retromolar canal three millimeters beneath the mesial aspect of the retromolar foramen were all measured. (Figure 2)

The mean of linear measurements of the retromolar canal in the right and left sides were analyzed by paired sample t-test. Chi square test was used to analyze the frequency of measurements with regard to the retromolar canal. Pearson correlation coefficient was used to evaluate the relationship between linear measurements and age. Statistical analysis of the data was carried out using SPSS version 20. Level of significance was set at $p=0.05$.

Results

Of 151 inferior alveolar nerve canals evaluated in this study, retromolar canal was found in 11 cases

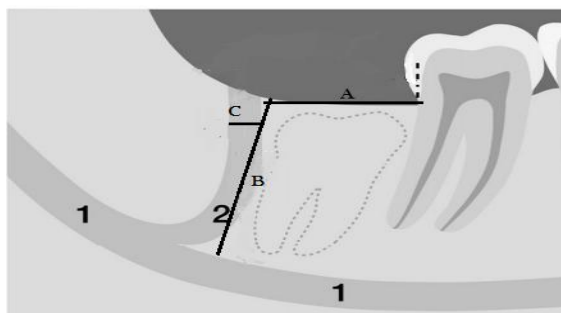


Figure 2. Schematic view of the linear measurements made with regard to the retromolar canal

(7.3%). The frequency of retromolar canal was not significantly different based on sex and side of involvement ($p=0.146$). No significant difference was noted in the prevalence of retromolar canal in the right and left sides ($p=0.763$).

Table 1 shows the mean distance from the retromolar canal to the distal of the third molar tooth, the mean height of the canal and width of the retromolar canal 3mm below the retromolar foramen.

According to t-test, no significant difference existed in the horizontal distance of the retromolar canal ($p=0.57$), height of retromolar canal ($p=0.63$) and width of retromolar canal ($p=0.72$) in the right and left sides. No significant association was noted between sex and horizontal distance of the retromolar canal ($p=0.44$) or width of retromolar canal ($p=0.33$). However, a significant association existed between the height of retromolar canal and sex ($p=0.02$) (Table 2).

According to the Pearson's correlation test, no significant association existed between age group and horizontal distance of retromolar canal ($p=0.62$), height of retromolar canal ($p=0.84$) and width of retromolar canal ($p=0.27$). Also, the Pearson's correlation test showed an inverse correlation between age group and horizontal distance of retromolar canal ($r=-0.57$) and vertical distance of retromolar canal ($r=-0.06$).

A significant correlation was found between age group and width of retromolar canal as well ($r=0.36$) (Table 3, Figures 3-7). Table 4 shows the frequency of different types of retromolar canal. B2 type was not seen on any CBCT scan.

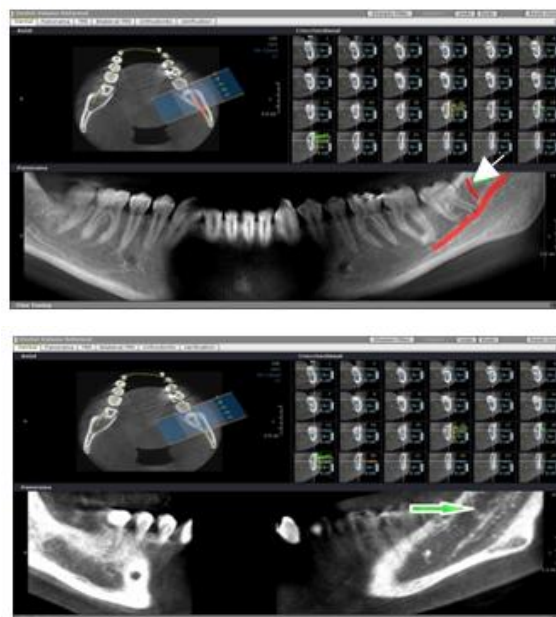


Figure 3. Retromolar canal on the reconstructed panoramic images (green arrow in the left side of the patient)

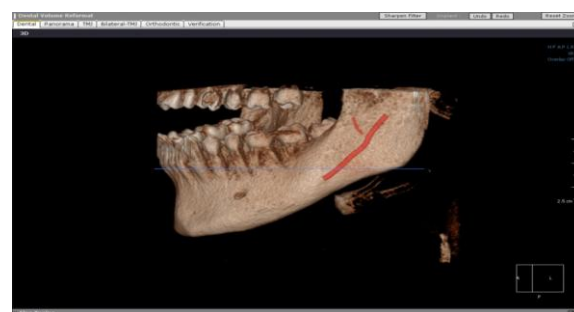

Figure 4. Retromolar canal in the three-dimensional view

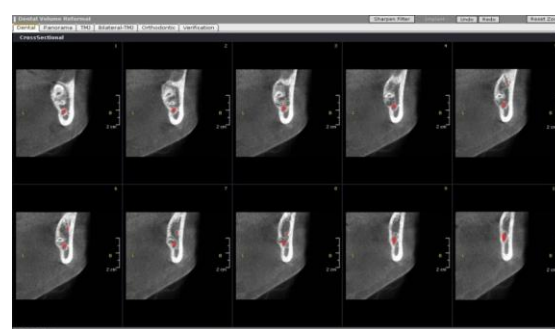


Figure 5. Retromolar canal in cross sectional views

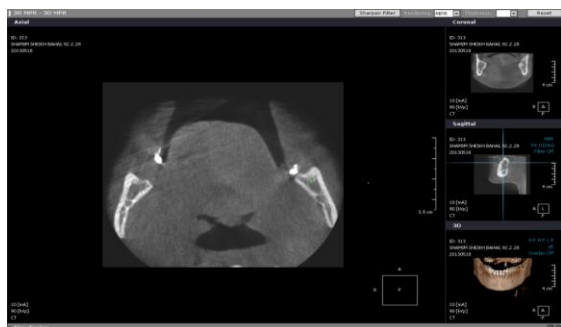

Figure 6. Retromolar canal in the axial view. Green circle indicates the retromolar foramen

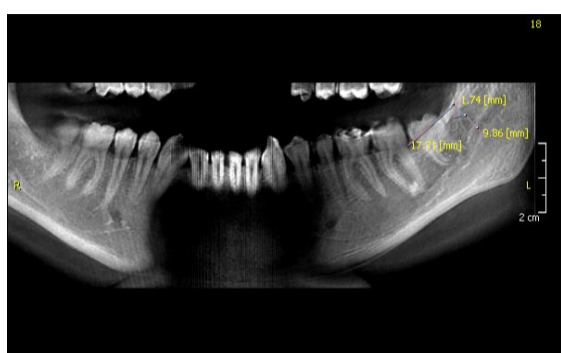


Figure 7. Linear measurements made on the reconstructed panoramic view with 8mm thickness

Discussion

This study aimed to compare the fracture Based on the results, the prevalence of retromolar canal was 7.3% (11 cases). The prevalence of retromolar canal on CBCT scans has reported to be 6.1 to 72% in previous studies [6,8,9]. Von Arx et al. reported the prevalence of retromolar canal to be 25.6% [7]. This rate was reported to be 10.2% by Kang et al, in Korea [10], 21.9% by Narayana et al, in India [9], 0.9% by Naitoh et al, [11], 4.3% by Singh et al, [2] and 35% by Sanchis et al [12]. Such variability in results may be due to racial, ethnic and geographical differences.

In our study, of 49 CBCT scans on which, inferior alveolar canals were visible bilaterally, only two cases had bilateral retromolar canals; six other cases had unilateral retromolar canals. In a study by von Arx et al, [7] on 21 bilateral mandibular canals, four cases of bilateral retromolar canals were found. Priya et al. evaluated 157 dry

mandibles and reported the prevalence of bilateral retromolar canals to be 5.1% [13].

Based on our results and those of von Arx et al, [7] the prevalence of retromolar canal in females was higher than in males but Ossenberg et al, [6] and Pyle et al, [14] reported that the prevalence of retromolar canal was higher in males. Type A1 had the highest prevalence (41%) in the study by von Arx et al; while in our study, type C had the highest prevalence (45.5%). B2 type was not found in any case. In the study by von Arx et al, type C was not seen at all [7].

The mean distance from the mesial surface of retromolar foramen to the cemento-enamel junction at the distal surface of second molar was 15.16mm in the study by von Arx, which was 3mm greater than the value obtained in our study (12.76mm). This difference may be related to the reference point of measurement. In the study by von Arx et al, the distance from the midpoint of retromolar foramen was measured while in our study, the distance from the mesial surface of foramen was recorded. Also, in the study by von Arx et al, presence of third molars was not an inclusion criterion [7]. However, third molar extraction can result in misplacement of second molar and affect the afore-mentioned horizontal distance.

Our results showed no significant association between age and horizontal distance of retromolar canal. Based on the Pearson's correlation test, an inverse correlation existed between age and horizontal distance. The right/left side and sex had no significant association with horizontal distance of retromolar canal. This result was in agreement with that of Bilecenoglu and Tuncer [15]. They evaluated the skulls and reported the mean horizontal distance to be 11.9mm.

The mean height of the retromolar canal from the midpoint of the retromolar foramen to the superior border of the inferior alveolar canal in our study was 6.66mm; however, in the study by von Arx et al, this value was reported to be 11.34mm. Such a difference in the results of the two studies may be attributed to the reference point of measurement and higher prevalence of retromolar canal (31 cases) in their study [7]. Moreover, in our study, the mean height of retromolar canal had no significant association with sex while in the study by von Arz et al, males had a higher mean height.

Table 1. The mean value of linear measurements of retromolar canal in millimeters

Variable	Number	Minimum length (mm)	Maximum length (mm)	Mean± standard deviation (mm)
Horizontal distance	11	2.1	17.9	12.7± 4.3
Height	11	2.8	11.1	6.6± 2.1
Width	11	0.88	2.9	1.7± 0.6

Table 2. The mean value of linear measurements of retromolar canal in the right and left sides in males and females

Variable	Mean± standard deviation (mm)		P value	Mean± standard deviation (mm)		P value
	Right	Left		Females	Males	
Horizontal distance of retromolar canal	13.4± 3.3	11.9± 5.5	0.57	11.3± 1.8	13.5± 5.2	0.44
Height of retromolar canal	6.9± 2.8	6.3± 1.3	0.63	7.7± 1.7	4.8± 1.7	0.02
Width of retromolar canal	1.7± 0.71	1.6± 0.51	0.72	1.9± 0.64	1.5± 0.57	0.33

Table 3. The relationship of age group and linear measurements

Linear measurements	Age group	
	P value	Pearson's correlation
Horizontal distance of retromolar canal	0.62	-0.57
Height of retromolar canal	0.84	-0.06
Width of retromolar canal	0.27	+0.36

In our study, this value was higher in females. But this does not mean that women had a greater height of mandible in the retromolar area because the retromolar canal length is defined as the distance between the mandibular canal and retromolar foramen. Thus, canal length depends on the position of retromolar foramen. In our study, height of retromolar canal had an inverse correlation with age. No significant correlation was found between the retromolar canal height and side of the mandible.

Table 4. The frequency of different types of retromolar canal

Type	Number	Percentage
A1	2	18.1
A2	1	9.1
B1	3	27.3
B2	0	0
C	5	35.5
Total	11	100

Conclusion

Based on the results, the prevalence of retromolar canal was 7.3% on CBCT scans and horizontal and vertical distances and width of retromolar canal had no significant association with the side of the mandible. Horizontal distance and width of retromolar canal had no significant association with sex and the height of the retromolar canal was greater in females than in males.

References

1. Auluck A, Pai KM, Mupparapu M. Multiple mandibular nerve canals: Radiographic observations and clinical relevance Report of 6 cases. *Quintessence Int.* 2007 Oct; 38(9):781-7.
2. Singh SK, Prabhu R, Mamatha G.P, Gupta A, Jain M. Morphologic variations in the mandibular canal: A retrospective study of panoramic radiographs. *J Oral Health Res.* 2010 Sept; 1(3): 106-12.
3. Malamed SF. *Handbook of local anesthesia*. 6th ed. St. Louis: Elsevier; 2013, 182,225,240.
4. Hargreaves KM, Cohen S, Berman LH. *Cohen's pathways of the pulp*. 10th ed. St. Louis: Mosby Elsevier; 2011: 700-1.
5. Ingle JJ, Bakland LK, Baumgartner JC, Ingle, JJ. *Ingle's endodontics* 6th ed. Hamilton: BC Decker; 2008,716.
6. Ossenberg NS. Retromolar foramen of the human mandible. *Am J Phys Anthropol.* 1987 May; 73(1):119-28.
7. Von Arx T, Hänni A, Sendi P, Buser D, Bronstein MM. Radiographic study of the mandibular Retromolar canal: An anatomic structure with clinical importance. *J Endod.* 2011 Dec;37(12):1630-5.
8. Sawyer DR, Kiely ML. Retromolar foramen: a mandibular variant important to dentistry. *Ann Dent.* 1991 Summer; 50(1):16-8.
9. Narayana K, Nayak UA, Ahmed WN, Bhat JG, Devaiah BA. The retromolar foramen and canal in south Indian dry mandibles. *Eur J Anat.* 2002 Dec; 6(3):141-6.
10. Kang JH, Lee KJ, Oh MJ, Choi H, Lee SR, Oh SH, et al. The incidence and configuration of the bifid mandibular canal in Koreans by using cone-beam computed tomography. *Imaging Sci Dent.* 2014 Mar; 44(1):53-60.
11. Naitoh M, Hiraiwa Y, Aimiya H, Arijji E. Observation of bifid mandibular canal using cone-beam computerized tomography. *Int J Oral Maxillofac Implants.* 2009 Jan-Feb; 24(1):155-9.
12. Sanchis JM, Penarrocha M, Soler F. Bifid mandibular canal. *J Oral Maxillofac Surg.* 2003 Apr; 61(4):422-4.
13. Priya R, Manjunath KY, Balasubramanyam. Retromolar foramen. *Indian J Dent Res.* 2005 Jan-Mar; 16(1):15-6.
14. Pyle MA, Jasinevivius TR, Lalumandier JA, Kohrs KJ, Sawyer DR. Prevalence and implications of accessory retromolar foramina in clinical dentistry. *Gen Dent.* 1999 Sept-Oct; 47(5): 500-3; quiz 504-5.
15. Bilecenoglu B, Tuncer N. Clinical and anatomical study of retromolar foramen and canal. *J Oral Maxillofac Surg.* 2006 Oct;64(10):1493-7.