

Prevalence and Pattern of Styloid Process Elongation and Calcification on Digital Panoramic Radiographs in an Iranian Population

Sh. Sakhdari¹, S. Saberi²✉, A.R. Shamshiri³.

¹ Assistant Professor, Department of Oral and Maxillofacial Radiology, Craniomaxillofacial Research Center, Islamic Azad University, Dental Branch, Tehran, Iran

² Dentist, Laser Research Center of Dentistry, Dentistry Research Institute, Tehran University of Medical Sciences, Tehran, Iran

³ Research Center for Caries Prevention, Dental Research Institute, Department of Community Oral Health, School of Dentistry, Tehran University of Medical Sciences, Tehran, Iran

Abstract

Background and Aim: Considering the importance of the clinical significance of the elongated styloid process, this study aimed to assess the prevalence and pattern of calcification and elongation of the styloid process on digital panoramic radiographs of an Iranian population.

Materials and Methods: This study was conducted on 500 digital panoramic radiographs of patients over 18 years old with visible styloid processes. The length of styloid processes was measured by software, and the length >30mm was considered as elongated. Prevalence and pattern of elongation and calcification were determined according to the classification proposed by Langlais. The associations of age, sex, and the jaw side of elongation was determined using generalized estimating equations with exchangeable matrix and binary logistic model.

Results: Elongation of styloid process was observed in 177 (17.7%) of 1000 evaluated processes were elongated. The Type I pattern of elongation (n=80, 45%) and type A pattern of calcification (n=69, 39%) had the highest frequency. Although the prevalence of elongation seemed to be higher in males, the difference was not significant (P=0.11). No significant association was observed between the side of jaw and elongation (P=0.54). Elongation was more common in the 40-59-year-old group compared to <40-year-old group (P=0.014).

Conclusion: The prevalence of elongated styloid process often considered as an anatomical variation and has been reported differently in the literature. Dentists should pay more attention to it during clinical examination especially in the case of pain in head and neck.

Key Words: Elongated Styloid Process Syndrome, Radiography, Panoramic, Digital, Calcification

➤ **Cite this article as:** Sakhdari Sh, Saberi S, Shamshiri A.R. Prevalence and Pattern of Styloid Process Elongation and Calcification on Digital Panoramic Radiographs in an Iranian Population. J Islam Dent Assoc Iran. 2018; 30(2):44-51. DOI: 10.30699/JIsdreir.30.2.44

✉ Corresponding author:
S. Saberi, Dentist, Laser
Research Center of Dentistry,
Dentistry Research Institute,
Tehran University of Medical
Sciences, Tehran, Iran

saberisogol@gmail.com

Received: 18 Nov 2017

Accepted: 13 March 2018

Introduction

Elongation of styloid process and its calcification are a common concern in dental clinical examinations [1]. Styloid process is a thin and long cylindrical bony prominence of the temporal bone.

It is originated from the Reichert's cartilage of the second branchial arch [2-3]. The length of the styloid process is measured from the point where the styloid process leaves the tympanic plate to its tip [1-2,4]. The typical length of the styloid process

is approximately 20-30mm. Within the normal range, it has been classified into two groups of short (<20mm) and long (>20mm) styloid process. A length >30mm is referred to as elongated process [5-6]. The prevalence of elongated styloid process has been reported up to 93% [7]. The leading cause of styloid ligament calcification has not been fully identified; however, several etiologies have been suggested including congenital elongation, increased serum levels of calcium, and endocrine gland disorders (especially in females) [8-9]. Calcification of the surrounding soft tissue of the styloid process increases the thickness of this process, not its length [2].

In 1937, Watt Eagle was the first that described the elongation of the styloid process could be associated with pain in the head-neck region and pressure on the carotid artery and cranial nerves. He named it the Eagle's syndrome [10-12]. This syndrome may cause symptoms such as pain in the neck and pharynx with/without a recurrent earache and pain in the mastoid region of the involved side. Pain during deglutition or sense of a foreign body in the throat might be another symptom; however, most patients are asymptomatic [1,12-13]. Panoramic radiography and clinical examinations usually confirm the diagnosis. Styloid process elongation can be seen on panoramic radiographs [1,14].

Some previous studies that focused mainly on the skulls, only evaluated the prevalence of elongation of styloid process and calcification patterns were not determined [15-17]. While some studies neglected to evaluate the correlation of elongated styloid process with age and sex [2,18], others found significant correlations between these factors [4,7,11,19].

Digital panoramic radiography is commonly used for primary evaluation of patients in dental offices due to depicting all teeth and both jaws using low radiation dose. Different studies have evaluated styloid process elongation and calcification; however, none of the previous studies have assessed the frequency and patterns of elongation and calcification of styloid process among the Iranian population using accurate classifications. Given the significance of this topic and the controversy in the results of previous studies, the present study aimed to assess the prevalence and

patterns of elongation and calcification of styloid process on digital panoramic radiographs of an Iranian population.

Materials and Methods

In this descriptive, cross-sectional study, digital panoramic radiographs of all patients over 18 years of age that referred to the Radiology Department of Azad University in spring and summer of 2014 were evaluated. Radiographs with good qualities on which, the styloid processes were clearly visible, and the patients were accurately placed in the device were selected. All radiographs had been taken with Villa X-ray unit (Rotograph Evo, Italy) with the exposure settings of 68kVp and 9mA by an expert technician.

Calibration was first performed for all radiographs, and then the size of styloid process was measured by Dental Studio Plus software. All measurements were multiplied by the magnification factor (1.3) of the device (Figure 1). Length >30mm was considered as elongation [2]. Length of the styloid process was measured from the point where it leaves the tympanic plate of the temporal bone to its tip (Figure 2). Measurements were made on a computer monitor (355G2, HP) with 1366x768 pixels resolution, screen brightness of 213.2 cd/m², the contrast of 174:1 and black level of 1.21 cd/m² under adequate lighting. All measurements were made by an experienced radiologist who was skillful in working with the software and in order to decrease measurement errors, all measurements were repeated twice with a one-month interval.

In this study, elongation patterns were classified into four categories as proposed by Langlais [1] as follows (Figure 3):

Type I: One-piece styloid process >30mm

Type II: Styloid process attached to the mineralized stylomandibular ligament or stylohyoid ligament with a joint-like structure

Type III: Interrupted segments of the mineralized ligament, creating the appearance of multiple pseudo articulation.

Type IV: Elongation of the styloid process due to distant ossification. This pattern is similar to the H-J classification pattern by McDonald-Jankowski DS [1].

Calcification patterns were also categorized as follows (Figure 4):

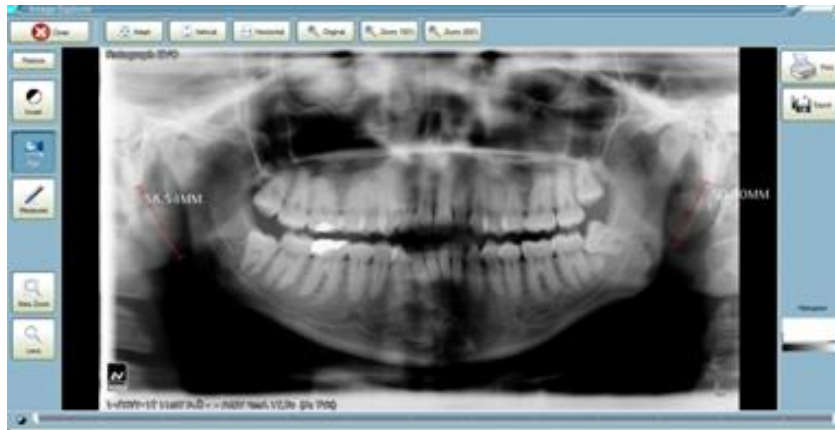

Figure 1. Dental Studio Plus software

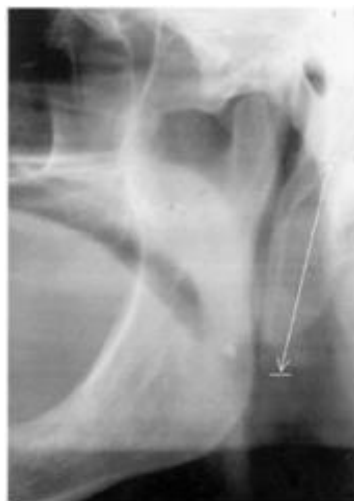

Figure 2. Measuring the length of styloid process

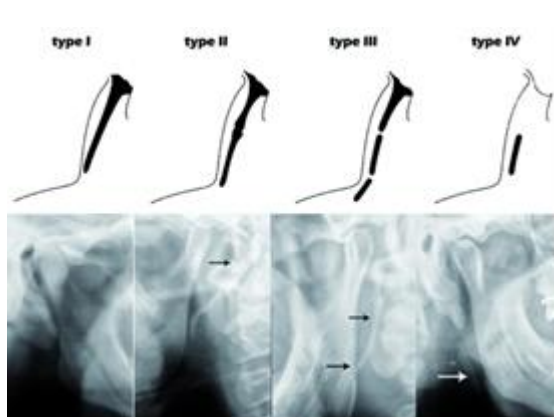


Figure 3. Elongation patterns of styloid process [1]

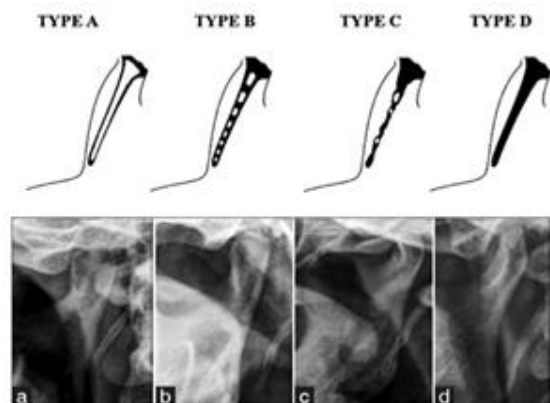


Figure 4. Calcification patterns of styloid process [1]

Type A: Styloid process with calcified external borders.

Type B: Incomplete calcification of styloid process along with central radiolucent areas.

Type C: Nodular pattern along with variable degrees of central radiolucency.

Type D: Calcified styloid process without internal radiolucency [1].

Statistical methods

The prevalence of elongation was determined with 95% confidence interval by Wilson Score Interval method. Due to related data in radiographies (e.g., right and left data from a radiography) the associations of age, sex and side of the jaw on its prevalence was determined using generalized estimating equations (GEE) with exchangeable matrix and binary logistic model.

Results

A total of 700 radiographs were examined and 500 radiographs in which the styloid processes appeared on both sides, were selected. Radiographs belonged to 282 females (56.4%) and 218 males (43.6%). The mean age of patients was 39.74 ± 12.37 years, ranging between 18 and 90 years.

Among the 1000 evaluated styloid processes, 177 (17.7%) showed elongation. Based on this rate, its actual prevalence rate, with 95% confidence interval, was estimated to be 15.3% to 20.1%. In other words, amongst 500 patients, 110 (22%) showed elongation of the styloid process which means with 95% confidence interval, the actual prevalence of elongated styloid process was 18.37% to 25.63%.

The relation between elongation of styloid processes with age and sex are presented in Table 1. Among 117 elongated styloid processes, 86 (48.6%) were on the left, and 91 (51.4%) were on the right side. Elongation of styloid process was not correlated with the side of the jaw ($P=0.54$). 13.4% of elongated styloid processes occurred bilaterally, and 8.6% of cases were unilateral. The mean increase in the length of styloid processes was 37.89 ± 8.37 mm which ranged from 30 to 79mm. The average lengthening of the left and right side were similar and was 37.86 ± 8.78 mm and 37.92 ± 8.02 mm, respectively.

The prevalence of different calcification and elongation patterns and their correlation with age and sex are summarized in Table 2. Based on results, given that the present study was cross-sectional, the differences in styloid process elongation patterns, between age groups, was not statistically significant ($P=0.27$); however, calcification patterns were related to sex ($P=0.02$). As shown in Table 2, the prevalence of Type A calcification was about two-times of the other types in men, while in females, Types C and D occurred almost twice as other types. Patterns of calcification were not correlated with age ($P=0.15$). There was no association between either elongation pattern or calcification type with the side of the jaw, P-values were 0.14 and 0.91, respectively. Overall, Type I elongation and Type A calcification patterns were more common in left (I=44, A=33) and right (I=63, A=36) sides. The right side elongation of the styloid process had a significantly higher prevalence in 40-59-year-old age group ($P=0.031$).

Table 1. Frequency of styloid process elongation in different age groups and gender

Variable/Elongation	Absence (n=823)	Presence (n=177)
Age group (years)		
<40	480(86%)	80(14%)
40-59	270(77%)	80(23%)
≥ 60	73(81%)	17(19%)
Sex		
Males	346(79%)	90(21%)
Females	477(85%)	87(15%)

Table 2. Associations of age, sex, and the jaw side with elongation and calcification patterns

--	Elongation pattern					p-value	Calcification pattern				p-value
	N(%)						N(%)				
	I	II	III	IV	A		B	C	D		
Age (years)	<40	33(41.3)	9(11.3)	22(27.5)	16(20)		31(38.8)	20(25)	12(15)	17(21.3)	
	40-59	38(47.5)	21(26.3)	16(20)	5(6.3)	0.27	26(32.5)	27(33.8)	7(8.8)	20(25)	0.15
	>60	9(52.9)	1(5.9)	7(41.2)	0(0)		12(70.6)	3(17.6)	0(0)	2(11.8)	
Sex	Females	40(46)	14(16)	21(24)	12(14)	0.92	25(29)	26(30)	12(14)	24(27)	0.02
	Males	40(44)	17(19)	24(27)	9(10)		44(49)	24(27)	7(7)	15(17)	
Side	Left	44(51.2)	11(12.8)	22(25.6)	9(10.5)	0.14	33(38.4)	25(29.1)	13(15.1)	15(17.4)	0.91
	Right	36(39.6)	20(22)	23(25.3)	12(13.2)		36(39.6)	25(27.5)	6(6.6)	24(26.4)	

Discussion

The occurrence of styloid process elongation varies vastly in different populations. In previous studies, the prevalence of elongated styloid process, diagnosed by panoramic radiographs, were reported between 3.7 to 93% [1,2,4,7,11,14,15,19,20]. However, in the study by Sudhakara Reddy et al, [1], only 1 to 6% of patients were symptomatic [1].

In the present study which was carried out on 500 patients, the prevalence of styloid process elongation was 22%. The majority of patients had bilateral increased length and the type I was more common among them. Furthermore, statistical analysis showed no gender preference in the styloid process elongation. Also, the rate of the elongated styloid process was higher in the 40-60 years old age group compared to the other groups. The prevalence of styloid process elongation in our study was similar to some of the previous studies [1,2,4,11]; however, results of several other studies were greatly different [7,14,15,19,20]. Many theories have been raised for elongation, calcification, and bone formation of the styloid process including the theory of reactive hyperplasia, reactive metaplasia, anatomic variance and ageing, and developmental anomaly due to loss of elasticity in the ligament simulating tendinosis [21,22].

In our study, we set the starting point of measurement at the point where the styloid process leaves the tympanic plate of temporal bone. This method of measurement was similar to a few of the previous studies and subsequently similar results were obtained [1,2,4,11,15]. However, in a number of studies, the starting point of measurement was the external auditory meatus, and some other studies set this point at the line connecting the nasal spine to the mastoid [7,9,20], and this could be the reason for differences between the various studies.

Sudhakara Reddy et al. [1] carried out a study in 2013 on 260 patients (520 styloid processes). Elongation of the styloid process was reported in 29% of cases which was higher than the present study. The method of measurement was similar to our study, and the type I elongation and type D calcification were reported to be the most common. Unlike our study, no significant relationship

between age and the length of the styloid process was discovered. However, similar to the present study, no significant relation between gender, age, and the pattern of elongation and calcification was found [1]. The relationship between age and elongation of the styloid process seems to be logical, while, it cannot affect the pattern of elongation. In the Sudhakara Reddy et al. [1] study, most patients were older compared to the present study, and this could be the reason for the lack of significant relationship between age and styloid process elongation in their study.

In Alpoz et al. [2] study in 2014, 1600 patients participated and 27.1% had elongated styloid process which was similar to the prevalence occurred in our study. Even though the classification of elongation and calcification in this study was different from ours, they have reached a similar conclusion and found no correlation between the gender and elongation whereas the age had a significant effect on the elongated styloid process. Also, similar to our study, there was a lack of statistically significant relationship between patterns of elongation and calcification with the age and gender [2].

In More and Asrani's [11] study in 2010 which was carried out on 500 patients, elongation of the styloid process was reported in 19.4% of patients and the type I elongation pattern was the most prevalent. They discovered that men in the age group of 31-50 and above 70 years old were the most common groups to have an elongated styloid process, and the relationship between age and elongation was also found to be significant [11]. Also, comparable to our study, they confirmed a significant relationship between gender and elongation, although, in their study, elongation was more prevalent in men.

The prevalence of styloid elongation was 38.57% in Lins et al. [20] study; it was higher than most studies which could be related to their method of measurement. However, the more occurrence of type B calcification and type I elongation was similar to our findings. Also, age was reported to have a statistically significant relationship with elongation [20].

Bagga et al. [19] employed a similar measurement method to Lins et al. [20] and reported elongation of the styloid process in 52.1% of patients which

could be the reason of the higher prevalence compared to our study.

Bagga et al. [19] indicated that Type I elongation pattern was the most prevalent, and similar to our study the prevalence rate was higher in men [19]. Similar to our results, they affirmed no significant relationship between gender and pattern of elongation and calcification.

Roopashri et al. [14] reported similar results to the present study including that the Type I elongation and bilateral elongation were more prevalent, and the prevalence rate was higher in higher aged patients groups compared to younger subjects. However, they reported a higher prevalence in women which was different to our findings [14].

The results of Shaik et al. [7] study in 2013, showed a prevalence of 63.2% of the elongated styloid process in males and 36.8% in females [7]. Their results was consistent with our study which could be because of the different method of measuring the styloid process. The Prevalence of elongated styloid process in men and the higher age groups were greater compared to the present study. Also, elongation patterns of Type I and calcification of Type A were more common in Shaik et al. [7] study, similar to our results.

In a study conducted in Iran in 2015 [23], women with low bone mineral density (BMD) have shown twice elongated styloid process compared to normal population [23]. Contrary to the Okabe et al. [24] findings, Hamedani et al. [23] indicated that the increase in the styloid process length was due to ectopic calcification in menopausal women. Okabe et al. [8] found that there was a positive relation between serum calcium and phosphorus levels in patients with styloid process elongation. Nevertheless, despite their findings, Gokce et al. [24] presumed that the definite cause of elongated styloid process had not been found and more studies are needed in order to verify the ectopic calcification theory [24].

Elongating the styloid process with age has been confirmed by several studies [4,7,11,14,19,23]. In the present study, a higher prevalence rate of the elongated styloid process was observed in age groups over 40 years old.

It seems despite several studies on the styloid process elongation, only the impact of age has been verified to some extent and the exact etiology

has not been established. The impact of factors such as sex and systemic conditions on styloid process elongation require more investigations [12].

Conclusion

Elongation of the styloid process had a variable prevalence rates in our study. Considering calcification and elongation patterns can be identified easily using panoramic radiographs, this method can be used to diagnose patients suffering from pain in the head and neck region.

References

1. Sudhakara Reddy R, Sai Kiran Ch, Sai Madhavi N, Raghavendra MN, Satish A. Prevalence of elongation and calcification patterns of elongated styloid process in south India. *J Clin Exp Dent*. 2013 Feb; 5(1): e30–e35.
2. Alpoz E, Akar GC, Celik S, Govsa F, Lomcali G. Prevalence and pattern of stylohyoid chain complex patterns detected by panoramic radiographs among Turkish population. *Surg Radiol Anat*. 2014 Jan;36(1):39-46.
3. Oztas B, Orhan K. Investigation of the incidence of stylohyoid ligament calcifications with panoramic radiographs. *J Investig Clin Dent*. 2012 Feb; 3(1):30-5.
4. Mirshekar A, Abesi F, Mehdizadeh M, Khanbabapour M, Khafri S. Radiological Assessment of the Length of Styloid Process on Panoramic Radiography. *J Mazand Univ Med Sci*. 2014; 24(112):123-6.
5. Ilguy M, Ilguy D, Guler N, Bayirli G. Incidence of the type and calcification patterns in patients with elongated styloid process. *J Int Med Res*. 2005 Jan-Feb; 33(1):96-102.
6. Koshy JM, Narayan M, Narayanan S, Priya BS, Sumathy G. Elongated styloid process: A study. *J Pharm Bioallied Sci*. 2015 Apr; 7(Suppl 1):S131-133.
7. Shaik MA, Naheeda, Kaleem SM, Wahab A, Hameed S. Prevalence of elongated styloid process in Saudi population of Aseer region. *Eur J Dent*. 2013 Oct-Dec; 7(4):449-454.
8. Okabe S, Morimoto Y, Ansai T, Yamada K, Tanaka T, Awano S, et al. Clinical significance and variations of the advanced calcified styloid complex detected by a panoramic radiographs

- among 80-year-old subjects. *Dentomaxillofac Radiol.* 2006 May; 35(3):191-9.
9. Ferrario VF, Sigurta D, Daddona A, Dalloca L, Miani A, Tafuro F, et al. Calcification of the stylohyoid ligament: Incidence and morphoquantative evaluation. *Oral Surg Oral Med Oral Pathol.* 1990 Apr; 69(4):524-9.
10. Ferreira PC, Mendanha M, Frada T, Carvalho J, Silva A, Amarante J. Eagle syndrome. *J Craniofac Surg.* 2014 Jan; 25(1):e84-6.
11. More CB, Asrani MK. Evaluation of the styloid process on digital panoramic radiographs. *Indian J Radiol imaging.* 2010 Nov;20(4):261-265.
12. Elimairi I, Baur DA, Altay MA, Quereshy FA, Minisandram A. Eagle's Syndrome. *Head Neck Pathol.* 2015 Dec; 9(4):492-5.
13. Dou G, Zhang Y, Zong C, Chen Y, Guo Y, Tian L. Application of surgical navigation in styloidectomy for treating Eagle's syndrome. *Ther Clin Risk Manag.* 2016 Apr 12; 12:575-83.
14. Roopashiri G, Vaishali MR, David MP, Baig M. Evaluation of elongated styloid process on digital panoramic radiographs. *J Contemp Dent Pract.* 2012 Sep 1; 13(5):618-22.
15. Ghafari R, Hosseini B, Shirani AM, Manochefrifar H, Saghaye S. Relationship between the elongated styloid process in panoramic radiographs and some of the general health conditions in patients over 40 years of age in the Iranian population. *Dent Res J (Isfahan).* 2012 Dec; 9(Suppl 1): S52-S56.
16. Patil S, Ghosh S, Vasudeva N. Morphometric study of the styloid process of temporal bone. *J Clin Diagn Res.* 2014 Sep; 8(9):AC04-AC06.
17. Natsis K, Repousi E, Noussios G, Papathanasiou E, Apostolidis S, Piagkou M. The styloid process in a Greek population: an anatomical study with clinical implications. *Anat Sci Int.* 2015 Mar; 90(2):67-74.
18. de Andrade KM, Rodrigues CA, Watanabe PCA, Mazzetto MO. Styloid process elongation and calcification in subjects with tmd: clinical and radiographic aspects. *Braz Dent J.* 2012; 23(4): 443-50.
19. Bagga MB, Kumar CA, Yeluri G. Clinicoradiologic evaluation of styloid process calcification. *Imaging Sci Dent.* 2012 Sep; 42(3): 155-161.
20. Lins CC, Tavares RM, da Silva CC. Use of Digital Panoramic Radiographs in the Study of Styloid Process Elongation. *Anat Res Int.* 2015; 2015: 474615.
21. Steinmann EP. Styloid syndrome in absence of an elongated process. *Acta otolaryngol.* 1968 Oct; 66(4):347-56.
22. Camarda AJ, Deschamps C, Forest D. I. Stylohyoid chain ossification: A discussion of etiology. *Oral Surg Oral Med Oral Pathol.* 1989 May;67(5):508-14.
23. Hamedani S, Dabbaghmanesh MH, Zare Z, Hasani M, Torabi Ardakani M, Shahidi S. Relationship of Elongated Styloid Process in Digital Panoramic Radiography with Carotid Intima Thickness and Carotid Atheroma in Doppler Ultrasonography in Osteoporotic Females. *J Dent (Shiraz).* 2015 Jun; 16(2):93-99.
24. Gokce C, Sisman Y, Sipahioglu M. Styloid Process Elongation or Eagle's Syndrome: Is There Any Role for Ectopic Calcification? *Eur J Dent.* 2008 July; 2:224-228.