

Assessment of Frequency and Anatomical Characteristics of Haller Cells in Cone-Beam Computed Tomography Scans of Patients Referring to a Private Oral and Maxillofacial Radiology Clinic During 2015-2017

S. Shahab¹, S. Sarikhani², M. Eslami Manouchehri², P. Yazdanpanah³✉

¹ Assistant Professor, Department of Oral and Maxillofacial Radiology, School of Dentistry, Shahed University of Medical Sciences, Tehran, Iran

² Assistant Professor, Department of Oral and Maxillofacial Radiology, School of Dentistry, Golestan University of Medical Sciences, Gorgan, Iran

³ Dentist, Health Care Center, School of Dentistry, Mashhad University of Medical Sciences, Mashhad Iran

Abstract

Background and Aim: Haller cells are one of the anatomical variations in the orbital area, which are important in endoscopic surgical procedures and have a role in the pathogenesis of some diseases including sinusitis and chronic craniofacial pain. The frequency of Haller cells has been reported in a wide range, which can be attributed to several factors. The purpose of this study was to determine the frequency and anatomical characteristics of Haller cells.

Materials and Methods: This descriptive study was performed on 381 patients referring to a private oral and maxillofacial radiology clinic during 2015-2017. These patients needed cone-beam computed tomography (CBCT) for various reasons. All CBCT scans were observed by a radiologist. The results were statistically analyzed by Chi-square test using SPSS version 16.0 software.

Results: From 381 patients, 34 patients (8.9%) had Haller cells. Sixteen patients (47.05%) had Haller cells on the right side, 15 patients (44.11%) showed these cells on the left side, while 3 patients (8.82%) had these cells on both sides. On the right side, the oval shape showed the highest frequency (n=9; 47.3%). 36.8% and 15.7% of the right-sided Haller cells were round (n=7) and pyramidal (n=3), respectively. On the left side, the circular shape had the highest frequency (n=8, 44.4%). Furthermore, 27.7%, 16.7%, and 11.1% of the left-sided Haller cells were oval (n=5), pyramidal (n=3), and teardrop-shaped (n=2), respectively.

Conclusion: The prevalence of Haller cells in our study was 8.9%. Genetic and racial factors, radiographic techniques, and the age range of patients are some of the reasons for different results.

Key Words: Haller Cells, Cone-Beam Computed Tomography, Ethmoid Sinus, Anatomic Variation

➤ **Cite this article as:** Shahab S, Sarikhani S, Eslami Manouchehri M, Yazdanpanah P. Assessment of Frequency and Anatomical Characteristics of Haller Cells in Cone-Beam Computed Tomography Scans of Patients Referring to a Private Oral and Maxillofacial Radiology Clinic During 2015-2017. *J Islam Dent Assoc Iran.* 2018; 30(3):100-105. DOI: 10.30699/JIsdrei.30.3.100

✉ Corresponding author:
P. Yazdanpanah, Dentist, Health Care Center, School of Dentistry, Mashhad University of Medical Sciences, Mashhad Iran

parisayp@yahoo.com

Received: 2 Sep 2017

Accepted: 2 March 2018

Introduction

Haller cells were first detected by Albrecht von Haller in 1765 [1]. The other names of this anatomical variation are maxilloethmoidal cells and infraorbital ethmoidal air cells [2-4]. These ethmoidal cells advance into the orbital floor or the

roof of the maxillary sinus, near the maxillary ostium, and may build the lateral wall of the infundibulum [5]. This makes them a potential key location in the pathogenesis of recurrent maxillary sinusitis because of disturbing the normal pattern of mucociliary flow [1].

Haller cells have different shapes such as ovoid, round, heart-shaped, pyramidal, and teardrop-shaped. These cells are radiolucent and can be unilocular or multilocular with a smooth border which may or may not appear corticated, and are located medial to the infraorbital foramen [5].

The incidence of Haller cells has been reported to have a range from 2% to 45%, and often, they do not have any symptoms [6]. Haller cells have different sizes and can cause various complications. Small cells may cause sinusitis and headache, the same as large cells; therefore, it can be presumed that there is no correlation between the size of the cells and the symptoms [4]. Haller cells are often found randomly. Their pathophysiological significance is associated with the stenosis of the maxillary ostium or the ethmoidal infundibulum [1]. Furthermore, in endoscopic surgeries, there is a risk of accidentally entering the orbit [5].

Cone-beam computed tomography (CBCT) is an imaging technique in dentistry, maxillofacial surgery, and otorhinolaryngology. It is a digital three-dimensional (3D) radiographic technique that provides isometric images in all three planes [4]. CBCT scans involve a lower radiation exposure and are less expensive compared to conventional CT scans. At present, CBCT is recommended for further examination of the maxillary sinus when two-dimensional (2D) radiographs do not provide enough information [4].

A study reported the prevalence of Haller cells to be 68% [1], while another study has reported the prevalence of 3.5% [2]. Because of the clinical importance of Haller cells and limited information with regard to this variation in Iran, the purpose of the current study was to evaluate the prevalence of Haller cells in patients referring to a private oral and maxillofacial radiology center in Tehran during 2015-2017.

Materials and Methods

This cross-sectional study evaluated CBCT images for the presence of Haller cells in patients referring to a private oral and maxillofacial radiology clinic in Tehran.

All CBCT scans were acquired by Newtom™ VGi scanner (QR s.r.l, Verona, Italy), with a 6.5×12-mm field of view (FOV), voxel size of 0.3 mm,

and kilovoltage peak (kVp)=110. The radiologist could change the contrast and brightness of the images. The information of each patient such as age, gender, the presence or absence of Haller cells, the location of these cells, and the size and shape of each cell was recorded by a radiologist. The shapes of these cells were categorized as ovoid, round, teardrop-shaped, and pyramidal [8]. The size of each cell was categorized as less than 2 mm (small), between 2 mm and 4 mm (medium), and larger than 4 mm (large) [1]. Chi-square test was used to compare the correlation between the shape and the location of Haller cells with independent descriptive variables. All statistical analyses were performed using SPSS software (version 16.0; IBM Co., Chicago, IL, USA). The level of significance was set at $P < 0.05$.

Results

From 381 patients, 165 were men (43.3%), and 216 were women (56.7%), and they ranged in age from 11 to 95 years (mean=51.2±16.0 years).

Haller cells were observed in 34 patients (8.9%). These cells were detected on the right side in 16 patients (47.05%), on the left side in 15 patients (44.11%), and bilaterally in 3 patients (8.82%; Table 1).

On the right side, the ovoid shape showed the highest frequency (n=9, 47.3%), followed by round (n=7, 36.8%) and pyramidal shapes (n=3, 15.7%; Table 2).

On the left side, the round shape showed the highest frequency (n=8, 44.4%). The frequency of other shapes on the left side was as follows: ovoid (n=5, 27.7%), pyramidal (n=3, 16.7%), and teardrop-shaped (n=2, 11.1%), and the shapes of bilateral Haller cells were round (n=2) and ovoid (n=1; Table 3).

On the left side, large Haller cells showed the highest frequency (n=15, 83.3%), while three Haller cells were medium-sized (16.7%), and none of them was small.

On the right side, large Haller cells had the highest frequency (n=18, 94.7%), while one of them was medium-sized (5.3%), and none of them was small. In our study, most of the patients with Haller cells were in the age range of 50-59 years (26.4%) and 40-49 years (23.5%; Diagram 1).

Chi-square test showed no significant correlation

Table 1. Frequency of Haller cells according to their shape and location

--	Shape				Total
	Pyramidal N(%)	Ovoid N(%)	Teardrop-shaped N(%)	Round N(%)	
Left	3(20)	4(26.7)	2(13.3)	6(40)	15
Location Right	3(18.7)	8(50)	0	5(31.2)	16
Bilateral	0	1(33.3)	0	2(66.7)	3

Table 2. Frequency of different shapes of Haller cells in males and females on the right side

--	Shape				--
	Male	Ovoid N(%)	Pyramidal N(%)	Round N(%)	
Gender Female		1(20)	2(40)	2(40)	5
Total		8(57.1)	1(7.1)	5(35.7)	14
		9(47.3)	3(15.7)	7(36.8)	19

Table 3. Frequency of different shapes of Haller cells in males and females on the left side

--	Shape				Total
	Pyramidal N(%)	Ovoid N(%)	Teardrop-shaped N(%)	Round N(%)	
Left	3(20)	4(26.7)	2(13.3)	6(40)	15
Location Right	3(18.7)	8(50)	0	5(31.2)	16
Bilateral	0	1(33.3)	0	2(66.7)	3

between the age and the presence of Haller cells (P=0.759). Chi-square test showed a significant correlation

between the gender and the presence of Haller cells (P>0.05). The analyses showed that Haller cells have the highest frequency in women (Diagram 2).

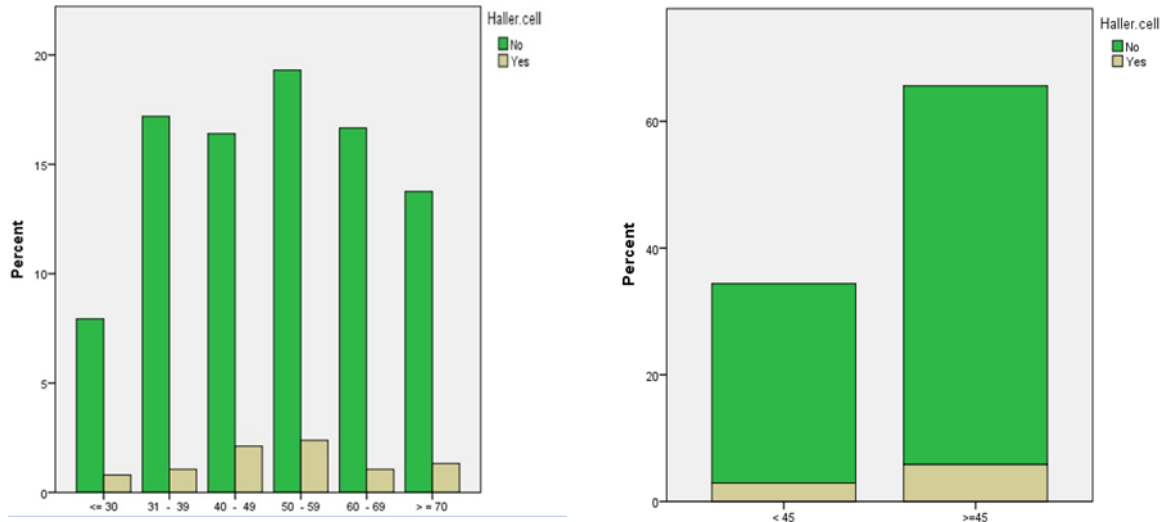


Diagram 1. Percentage of the presence or absence of Haller cells in different age groups

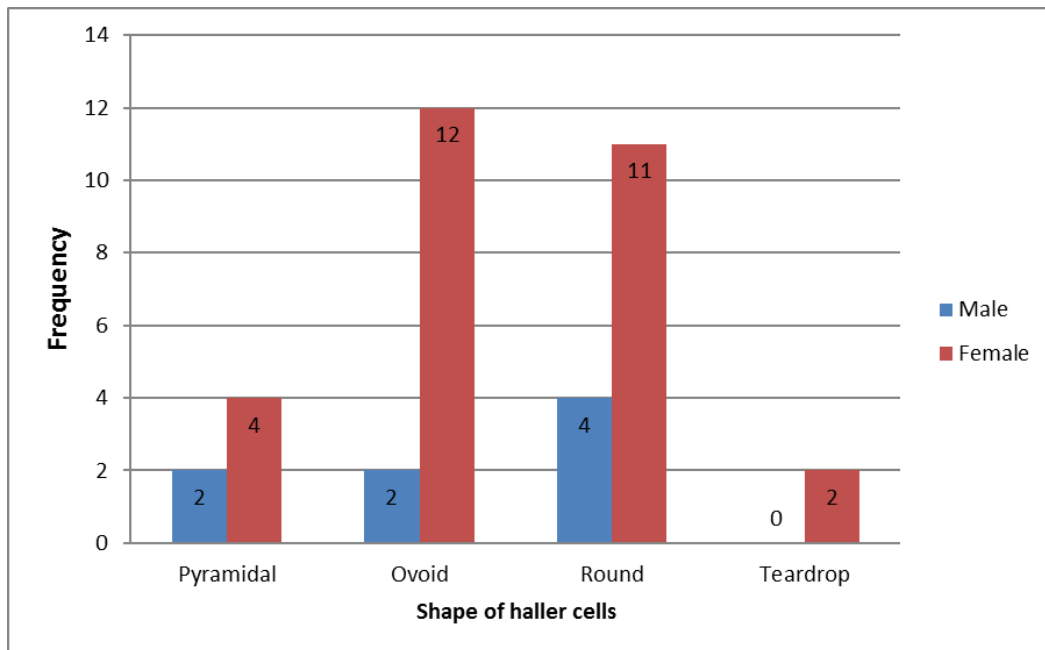


Diagram 2. Frequency of different shapes of Haller cells in males and females

Discussion

The prevalence of Haller cells has a variable range from 2% to 45% [6]. One reason for this variable range is the differences in the definition of these cells. Other causes are the differences in race, age range, and different techniques of imaging [2].

We found a prevalence of 8.9% for Haller cells, similar to the results of studies by Adeel et al [7] and Wani et al [8]. CBCT images were evaluated in the current study. CBCT is a volumetric imaging technique that can display each Haller cell separately. In multislice CT scans, Haller cells may not be seen at each interval; this actually demonstrates the benefit of using the CBCT method for the precise determination of Haller cells with a lower dose of radiation. The low prevalence of Haller cells in our study can be due to the studied population and our sample size. On the other hand, in a study by Khojastepour and colleagues [2], the prevalence of Haller cells during the review of CBCT scans was 68%. This great difference in the number of Haller cells compared to our study can be attributed to the fact that Khojastepour and colleagues [2] examined the CBCT images only in the coronal plane, while we evaluated the CBCT images in all three planes.

In the current study, 47.05% of Haller cells were on the right side, 44.11% were on the left side, and 8.82% were located bilaterally. The unilateral presence of Haller cells in our study is significant. In studies by Solanki et al [6] and Raina et al [9], the unilateral presence of Haller cells was significant as well. In previous studies, Haller cells were unilateral in most cases [5,6,9-11]. In the study by Solanki et al [6], from 192 Haller cells, 176 were unilateral, and 15 were bilateral, and the unilateral presence of Haller cells was statistically significant. In the study by Raina et al [9], from 96 Haller cells, 74 cases (77.1%) were unilateral, and 22 cases (22.9%) were bilateral, and unilaterality was statistically significant.

Bilateral presence of Haller cells has shown different prevalence rates [9,12,13]. In our study, Haller cells were located bilaterally in 8.82% of the cases. The differences in the prevalence may be due to factors such as the studied population, the definition of the hallmark cells, and the methods of imaging. On the other hand, the prevalence of bilateral Haller cells in our study is similar to that

reported by Solanki et al [6] and Pekiner et al [5]. In the study by Pekiner et al [5], the prevalence of bilateral Haller cells was 12%. Solanki et al [6] reviewed 192 panoramic radiographs and found bilateral Haller cells only on 15 radiographs.

In the present study, we also evaluated the location of Haller cells in males and females, and the highest frequency was detected in women as follows: on the right side (n=11, 68.8%), on the left side (n=12, 80%), and on both sides (n=3, 100%).

In the current study, Chi-square test showed no significant correlation between the age and the presence of Haller cells, and the highest cell frequency was detected in the age ranges of 50-59 and 40-49 years. In the study by Solanki et al [6], the maximum numbers of cells were seen in the age range of 18-28 years. Raina et al [9] reported the maximum number of cells in the age range of 18-30 years. One of the reasons for this difference is the difference in the studied population.

In the current study, Chi-square test showed a significant correlation between the gender and the presence of Haller cells as these cells were detected more frequently in women. Ahmad et al [14] reported similar results.

In our study, 82.3% of Haller cells were large, 17.7% were medium-sized, while none of them was small. In the study by Mathew et al [1], 28% of Haller cells were small, 21% were medium-sized, and 51% were large.

This study carefully examined the prevalence of Haller cells according to age, gender, shape, and frequency. Such description of ethmoidal cells can be used in the differential diagnosis for patients suffering from unexplained orofacial pain. It also helps in reducing the use of other expensive and aggressive modalities. The diagnosis of Haller cells can provide a preoperative overview for the surgeon to prevent the complications caused by entering these areas. Further studies with more advanced imaging modalities can confirm our findings and provide a more precise description of these cells.

Conclusion

The prevalence of Haller cells was found to be 8.9% in the present study. Genetic and racial factors, radiographic techniques, and the age range

of patients are some of the reasons for the differences in the reported results. The present study indicates that CBCT can be an appropriate modality for determining the presence of Haller cells.

References

1. Mathew R, Omami G, Hand A, Fellows D, Lurie A. Cone beam CT analysis of Haller cells: prevalence and clinical significance. *Dentomaxillofac Radiol.* 2013;42(9):20130055.
2. Khojastepour L, Mirhadi S, Mesbahi SA. Anatomical variations of ostiomeatal complex in CBCT of patients seeking rhinoplasty. *J Dent (Shiraz).* 2015 Mar;16(1):42-8.
3. Talaiepour AR, Sazgar AA, Bagheri A. Anatomic variations of the paranasal sinuses on CT scan images. *J Dent (Tehran).* 2005;2(4):142-6.
4. Miracle AC, Mukherji SK. Conebeam CT of the head and neck, part 2: clinical applications. *AJNR Am J Neuroradiol.* 2009 Aug;30(7):1285-92.
5. Pekiner FN, Borahan MO, Dumlu A, Özbayrak S. Infraorbital ethmoid (Haller) cells: a cone-beam computed tomographic study. *Oral Radiol.* 2014 Sep;30(3):219-25.
6. Solanki J, Gupta S, Patil N, Kulkarni VV, Singh M, Laller S. Prevalence of Haller's cells: a panoramic radiographic study. *J Clin Diagn Res.* 2014 Sep;8(9):RC01-RC04.
7. Adeel M, Rajput MS, Akhter S, Ikram M, Arain A, Khattak YJ. Anatomical variations of nose and para-nasal sinuses; CT scan review. *J Pak Med Assoc.* 2013 Mar;63(3):317-9.
8. Wani AA, Kanotra S, Lateef M, Ahmad R, Qazi SM, Ahmad S. CT scan evaluation of the anatomical variations of the ostiomeatal complex. *Indian J Otolaryngol Head Neck Surg.* 2009 Sep; 61(3):163-8.
9. Raina A, Guledgud MV, Patil K. Infraorbital ethmoid (Haller's) cells: a panoramic radiographic study. *Dentomaxillofac Radiol.* 2012 May; 41(4): 305-8.
10. Ali IK, Sansare K, Karjodkar FR, Vanga K, Salve P, Pawar AM. Cone-beam computed tomography analysis of accessory maxillary ostium and Haller cells: Prevalence and clinical significance. *Imaging Sci Dent.* 2017 Mar; 47(1): 33-7.
11. Fadda GL, Rosso S, Aversa S, Petrelli A, Ondolo C, Succo G. Multiparametric statistical correlations between paranasal sinus anatomic variations and chronic rhinosinusitis. *Acta Otorhinolaryngol Ital.* 2012 Aug;32(4):244-51.
12. Milczuk HA, Dalley RW, Wessbacher FW, Richardson MA. Nasal and paranasal sinus anomalies in children with chronic sinusitis. *Laryngoscope.* 1993 Mar;103(3):247-52.
13. Wanamaker HH. Role of Haller's cell in headache and sinus disease: a case report. *Otolaryngol Head Neck Surg.* 1996 Feb; 114(2): 324-7.
14. Ahmad M, Khurana N, Jaberi J, Sampair C, Kuba RK. Prevalence of Infraorbital Ethmoid (Haller's) Cells on Panoramic Radiographs. *Oral Surg Oral Med Oral Pathol Oral Radiol Endod.* 2006 May;101(5):658-61.